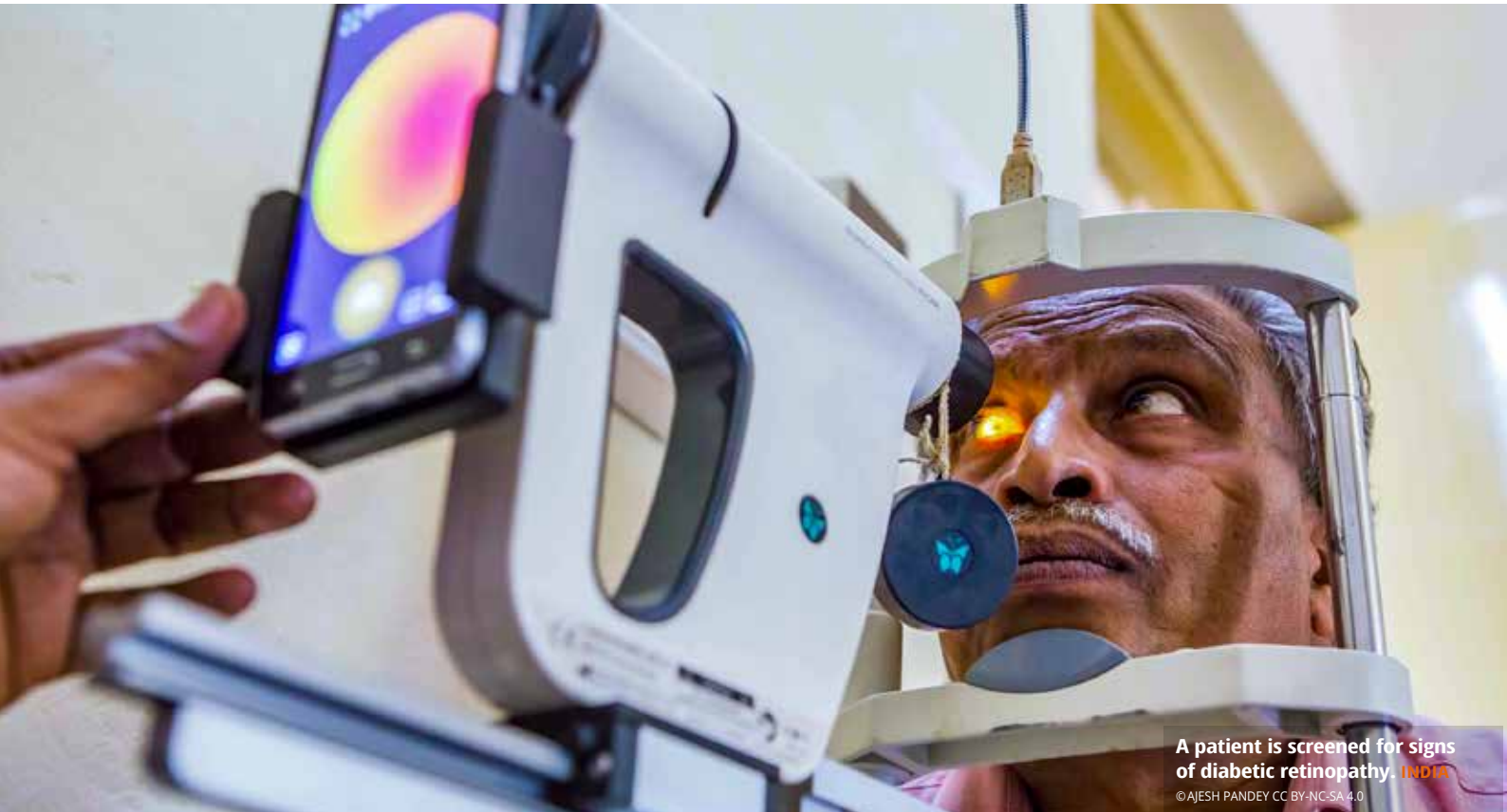

Community Eye Health Journal

VOLUME 36 • NUMBER 119 • 2023

Don't miss out
Download the free
Community Eye Health
Journal app today!
bit.ly/CEHJ-app



Preventing vision loss due to diabetic retinopathy

Links and referrals between diabetes and DR services are vital.



Nyawira Mwangi
Deputy Director
Academics, Kenya
Medical Training College,
Nairobi, Kenya.



Covadonga Bascaran
Clinical Research Fellow,
London School of
Hygiene and Tropical
Medicine, UK.


Diabetic retinopathy (DR) is a non-communicable eye disease caused by diabetes mellitus; it is also a leading cause of avoidable blindness. The landscape of screening, classification, grading, diagnosis, and treatment of DR has undergone tremendous changes since the *Community Eye Health Journal's* 2015 issue on DR. Technological advances in screening and grading, and the widespread use of anti-VEGF, are being seen in many DR programmes around the world.

The patient's journey

At the centre of any DR programme, the key consideration must always be the person with diabetes and their journey towards preventing visual loss caused by DR (Figure 1).

Throughout this journey, there must be effective linkages and referral mechanisms (Figure 1, blue arrows) to ensure that people with diabetes can progress through the different stages, from diabetes management, to DR screening, to diagnosis and treatment.

Figure 1 The patient's journey.





About this issue

Diabetic retinopathy is a leading cause of avoidable blindness. In this issue, we show how technological advances in screening and grading, and the use of anti-VEGF, can be included in DR programmes to provide patients with high quality, integrated care.

Contents

- 1 Preventing sight loss due to diabetic retinopathy**
Nyawira Mwangi and Covadonga Bascaran
- 4 Key considerations when choosing a retinal camera for diabetic retinopathy screening**
Covadonga Bascaran
- 6 Taking good retinal images for DR screening: considerations and practical tips**
Sharon Tench-Norbal
- 7 Considerations for storing and managing retinal images**
Charles Cleland
- 8 Grading diabetic retinopathy: an introduction**
Covadonga Bascaran
- 9 Comparing the International Clinical Diabetic Retinopathy (ICDR) severity scale**
Charles Cleland
- 10 Grading images for diabetic retinopathy: tips and guidelines**
Catherine Jamison, Laura Cushley, Katie Curran and Tunde Peto
- 13 Understanding and managing sight-threatening diabetic retinopathy**
David Yorston
- 15 Caring for a retinal camera**
Ismael Cordero
- 15 Artificial intelligence for DR screening**
Charles Cleland
- 16 Key community eye health messages**

From diabetes management to retinal screening

Everyone with a confirmed diagnosis of diabetes must have their eyes screened regularly in order to identify early signs of diabetic retinopathy. This is typically done yearly, or every two years.

How to support the patient's journey: As an eye care professional, ensure that health personnel caring for diabetes patients (e.g., diabetes nurses, physicians, and/or endocrinologists) know where and when to send their patients for retinal screening. They must tell their patients about the need for regular retinal checks in order to prevent visual impairment. They should also direct the patient to the screening site, which may be at the diabetes clinic or in primary or secondary care, depending on the context.

Sending diabetes patients for screening

Digital retinal cameras have changed the way DR screening is done and their use is now extended to many low- and middle-income settings. In this issue, we discuss the different types of cameras and the criteria to consider when choosing a camera, offer guidance on looking after the camera, provide practical tips on how to take good quality retinal images, and discuss considerations for storing and managing retinal images.

Once the retinal images have been taken, they are examined to look for signs of DR and graded according to the chosen classification system; this determines whether the person needs to be referred to the eye clinic for further examination by an ophthalmologist. Different countries and expert groups have created DR grading classification systems to suit their context, and it is a good idea to be aware of how different classifications relate to each other and to the widely used International Clinical Diabetic Retinopathy (ICDR) severity scale.

Depending on the DR programme and context, grading may be done by an ophthalmologist or a trained grader. Due to the large number of images that need to be graded, most settings are now training allied health personnel and even non-health workers to grade retinal images. Artificial intelligence technology, which has rapidly developed in the field of DR in the last decade, offers new opportunities to assist with the delivery of DR programmes through automated grading of retinal images. Many of the commercially available platforms for DR grading utilise the ICDR severity scale.

How to support the patient's journey: Once the image is taken, give the result to the patient immediately (if the person taking the images is also a trained grader) or, if the images are graded at a later date, contact the patient to share the results with them. If the patient is found to have DR, and must be referred, give them enough information about the importance of attending the eye clinic for a full examination, the risks of DR, and details about where the clinic is, and what they should expect when they attend.

Clinical diagnosis and management

When the person attends the eye clinic, a full eye examination, final diagnosis, and management plan is put together by the ophthalmologist. Typically, treatment for sight-threatening DR consists of laser and/or anti-VEGF injections. In this issue, we provide an update on the management of sight-threatening DR, including alternative laser delivery methods and the increasingly important role of anti-VEGF, particularly in resource-constrained settings.

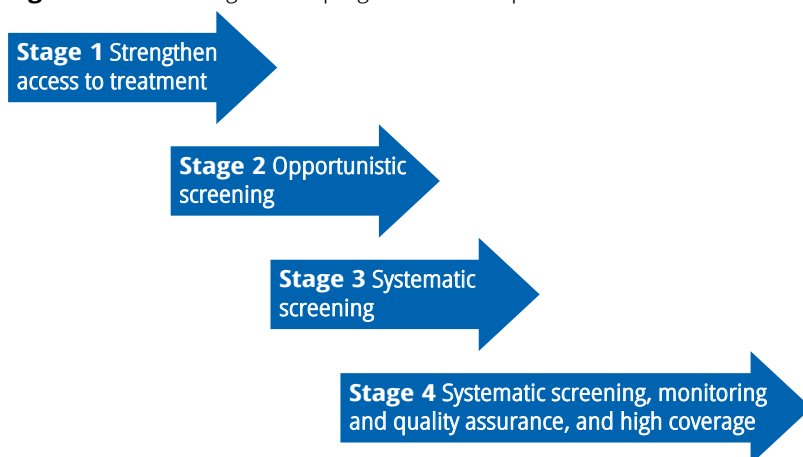
How to support the patient's journey: If the patient needs treatment, this must be explained in detail and the patient must consent to it. As DR treatment is delivered in more than one session, the patient must be informed of this early on, so that they can plan their attendance at the clinic.

Developing a DR screening and treatment programme

At programme level, strategies for efficient, high-coverage screening, referral, and effective treatment remain challenging. Whilst there are effective interventions to screen and treat DR that can prevent vision loss, few countries have successfully implemented high-coverage DR programmes.

DR programmes are likely to progress through different stages of development, with the ultimate goal of ensuring that all people with diabetes are screened and

Figure 2 The four stages in DR programme development



appropriately referred for treatment (Figure 2).

The first stage for any programme is to establish effective treatment services that are accessible and affordable to the population that they serve. These services are likely to vary in different contexts but, broadly, require the provision of laser treatment and anti-VEGF injections.

The second stage is to establish screening services for early identification of DR. This may begin as an opportunistic service, for example, screening the retina of all people with diabetes already attending a health facility for other reasons unrelated to their eyes. From there, screening may progress to being systematic, that is obtaining a register of all people diagnosed with diabetes and delivering regular screening to that population. A final stage would involve increasing the number of people that are systematically enrolled in the screening programme, aiming to achieve 80% coverage or more, and also embedding quality assurance in the programme so that the accuracy of screening can be monitored and maintained.

In summary, establishing good treatment services for DR is a priority in most countries, followed by delivering screening services for early identification of DR. Programmes must be designed with the patient's journey in mind, so that they can progress through the clinical pathway. Both the design of the programme and the patient journey will vary from setting to setting; the context and local needs should always be taken into consideration.

Subscribe

Visit <https://bit.ly/3uwMvf5>

Address for subscriptions

Community Eye Health Journal South Asia, Indian Institute of Public Health, Exit No: 17, Survey No 384, Towards, Himayat Sagar Main Road, near Outer Ring Road, Rajendra Nagar, Hyderabad, Telangana 500030, India.

Tel +91-40-49006000

Email editor@cehjsouthasia.org

Correspondence articles

We accept submissions of 800 words about readers' experiences in eye health. Contact:

editor@cehjsouthasia.org

Published by the International Centre for Eye Health, London School of Hygiene & Tropical Medicine.

Unless otherwise stated, authors share copyright for articles with the Community Eye Health Journal. Illustrators and photographers retain copyright for images published in the journal.

Unless otherwise stated, journal content is licensed under a Creative Commons Attribution-NonCommercial (CC BY-NC) license which permits unrestricted use, distribution, and reproduction in any medium for non-commercial purposes, provided that the copyright holders are acknowledged.

ISSN 0953-6833

Disclaimer

Signed articles are the responsibility of the named authors alone and do not necessarily reflect the views of the London School of Hygiene & Tropical Medicine (the School). Although every effort is made to ensure accuracy, the School does not warrant that the information contained in this publication is complete and correct and shall not be liable for any damages incurred as a result of its use.

The mention of specific companies or of certain manufacturers' products does not imply that they are endorsed or recommended by the School in preference to others of a similar nature that are not mentioned. The School does not endorse or recommend products or services for which you may view advertisements in this journal.

The Community Eye Health Journal is supported by:



South Asia Edition supported by:

TIJSSSEN
FOUNDATION





Covadonga Bascaran

Clinical Research Fellow, London School of Hygiene and Tropical Medicine, UK.

Key considerations when choosing a retinal camera for diabetic retinopathy screening

Retinal cameras are widely used in DR screening. There are several important aspects to consider when choosing a retinal camera, including how and where it will be used, and the images it is able to produce.



Figure 1 Diabetic retinopathy screening using a hand-held camera. **INDIA**

Screening people for diabetic retinopathy (DR) involves examining the retina of patients with diabetes to detect abnormal changes; this is usually done once a year.

The development of retinal cameras has sped up the process significantly. It is now possible to take photos of the retina that can be examined by a specially trained screener/grader, avoiding the need for an ophthalmologist to examine every patient. Thanks to the accuracy and speed of this approach, it has become the standard method for retinal examination in DR screening programmes.¹ This is particularly helpful due to the growing magnitude of diabetes worldwide, and the shortage of ophthalmologists available.

In recent years, retinal cameras have evolved considerably in both specification and cost. Since health budgets are often overstretched, investing in the right camera for a DR screening programme the first time will save costs later on.

Table-top or hand-held?

There are two main types of cameras: the traditional static camera which sits on top of a table (also known as a table-top camera), or a hand-held camera (see Table 1).

Table-top retinal cameras are large and heavy, and are mounted on a medical instrument table. They must be plugged into a power socket. Patients sit on a chair in front of the camera, with their chin positioned on the chin rest.

Hand-held retinal cameras are light, battery-powered cameras that can be used in any position that is comfortable for the patient.

Choosing between the type of camera depends on several factors, as set out below.

The location where the camera will be used

If the camera is going to be based at a hospital and doesn't need to be moved, and there is adequate, secure space, a table-top camera could be a good choice.

However, if a programme requires the camera to be used in different clinics, for example when screening at diabetes clinics in primary care facilities, a portable camera would be a better option.

The financial resources of the programme

Hand-held cameras are relatively inexpensive compared with table-top cameras, and may be a better option when resources are limited and/or when more than one camera is needed.

The personnel who will be taking the images

Ideally, cameras should be easy to operate by trained non-technical staff. Most table-top cameras come with automatic image-capturing capabilities that make them easy to use with relatively little training. In contrast, some hand-held cameras may require more manual input to achieve good images; therefore, more training and practice is required.²

The image quality

Generally, table-top cameras are more consistent at producing high quality images. When using hand-held cameras, there can be movement of the patient and of the screener, which affects the image focus and therefore the quality of the image. Some hand-held cameras come with an optional portable frame with a chin rest that allows for mounting on a table and makes image acquisition easier.

To dilate or not?

Some retinal cameras are marketed as being 'non-mydratric'; in other words, images can be taken without the need for pupil dilation. However, even with these cameras, the quality of the images is generally better if pupils are dilated. The decision to dilate or not should be taken depending on the needs of each programme and on local guidelines.³

General considerations

Once you have decided on the most appropriate type of camera for your screening programme and are evaluating different models, consider the following questions.

Does the camera produce images that meet the minimum specifications?

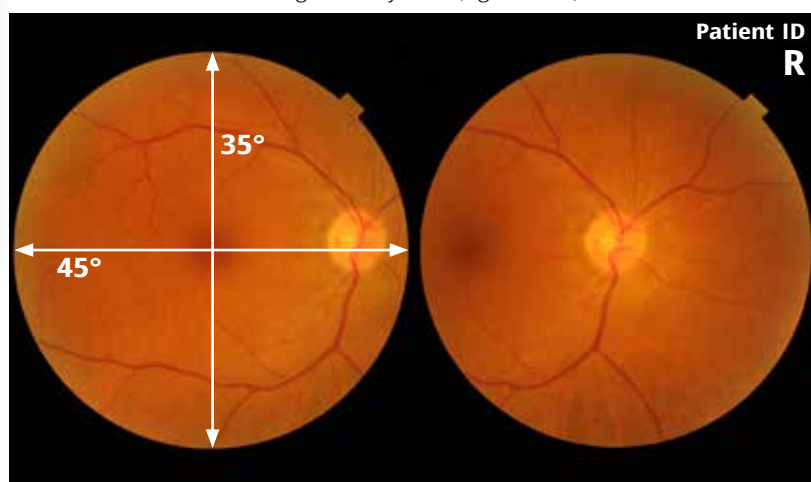The images produced by the retinal camera must meet these minimum specifications⁴:

- The minimum field of view should be 45° horizontally and 35° vertically (Figure 2), with a resolution of at least 30 pixels per degree.
- The camera software should be capable of identifying whether the image is of the right or left eye, and label the top right-hand corner of the image accordingly (Figure 2).
- The image colour should be representative of the colour that the operator would see by direct examination of the retina.
- There should be a patient identifier (patient ID) visible on the image; this is one of several standards for retinal imaging⁵ included in the DICOM standard (Figure 2).⁶

Does the camera itself meet quality standards?

It is important to ensure that the retinal camera complies with international quality standards. Two international standards that many companies seek

Figure 2 The minimum field of view produced by retinal cameras should be 45° horizontally and 35° vertically. Images should display the patient identification number and a label indicating which eye it is (right or left).



to comply with are the International Organization for Standardization's ISO 10940 (2009) standard, and the International Electrotechnical Commission's IEC 60601-1 standard. In some countries, retinal cameras must also be registered with national or regional bodies.

What servicing and support is available locally?

Ensure that the manufacturer gives at least 12 months warranty, and that the parts will be available for at least five years. You should ideally work with a distributor that has a local presence so that they can help with installation, servicing and repairs. If it is likely that the camera will need to be shipped to another country for repairs, you may wish to negotiate with the distributor to provide a camera on loan while repairs are being made, so that the screening programme is not interrupted.

References

- 1 Bascaran C, Zondervan M, Walker C, Astbury NJ, Foster A. Diabetic retinopathy in Africa. *Eye* (Lond). 2022;36(Suppl 1):1-3. doi:10.1038/s41433-022-01999-3
- 2 Gosheva M, Klameth C, Norrenberg L, Clin L, Dietter J, Haq W, Ivanov IV, Ziemssen F, Leitritz MA. Quality and learning curve of handheld versus stand-alone non-mydratric cameras. *Clin Ophthalmol*. 2017 Aug 31;11:1601-1606. doi: 10.2147/OPHT. S140064. PMID: 28919703; PMCID: PMC5587188.
- 3 Scanlon PH. Update on Screening for Sight-Threatening Diabetic Retinopathy. *Ophthalmic Res* 2019. 27:1-7
- 4 Equipment specifications: Fundus camera for diabetic retinopathy screening: non -mydratric. <https://www.iapb.org/learn/resources/equipment-specifications-fundus-camera-for-diabetic-retinopathy-screening/>
- 5 Digital Communications in Medicine (DICOM) Standard, Supplement 91. bit.ly/DICOM91 (PDF)
- 6 Lee AY, Campbell JP, Hwang TS, Lum F, Chew EY. Recommendations for Standardization of Images in Ophthalmology. *Ophthalmology*. 2021;128(7):969-970. bit.ly/AAOimages

Table 1 Features, advantages, and disadvantages of table-top and hand-held retinal cameras

	Table-top camera	Hand-held camera
Size and portability	Large, very difficult to move	Light, easy to move around (can be held in one hand)
Storage and security	Must be kept in a dedicated, secure (lockable) area with enough space for patient and operator	Smaller, portable, easy to store, e.g., in a safe or in a secure, locked cupboard
Cost	More expensive	More affordable
Image quality	Higher quality images, more consistent quality	Image quality not as good; quality also more variable
Ease of use (for the operator)	Easy to use. Has automatic image-capturing capabilities	Manual image capturing; requires more practice to take good quality images that are in focus
Patient comfort	Patients have to sit at the table and use the chin rest, which may be uncomfortable for some	Patient can be in any position that is comfortable for them



Sharon Tench-Norbal
Family Nurse Practitioner and DR Focal Point-Screener/Grader: Ministry of Health, Wellness and Elderly Affairs, Castries, St Lucia.

Taking good retinal images for DR screening: considerations and practical tips

Taking good retinal images is a vital step in screening for diabetic retinopathy. All measures should be taken to ensure that the images captured are relevant and of sufficiently good quality to ensure that no-one is misdiagnosed.

Diabetic eye screening allows people living with diabetes to benefit from early detection and treatment of sight-threatening diabetic retinopathy (DR). Screening is usually done by taking a photo of the back of the eye using a retinal camera. These photos or images should be of good quality, so that the person grading them can make an accurate assessment and refer people who need treatment.

What is a good quality image?

A good quality image is sufficiently clear to identify the anatomy of the fundus, including the macula, the optic disc, and the blood vessels. Commonly, photographs are taken in each eye: one of the optic disc (nasal image) and one of the macula (central image). These images are usually enough to enable the grader to identify any abnormalities. However, each image must be clear and in focus. If not, you will have to take extra images, which can be time consuming and lead to delays.

Tips for capturing a good quality image

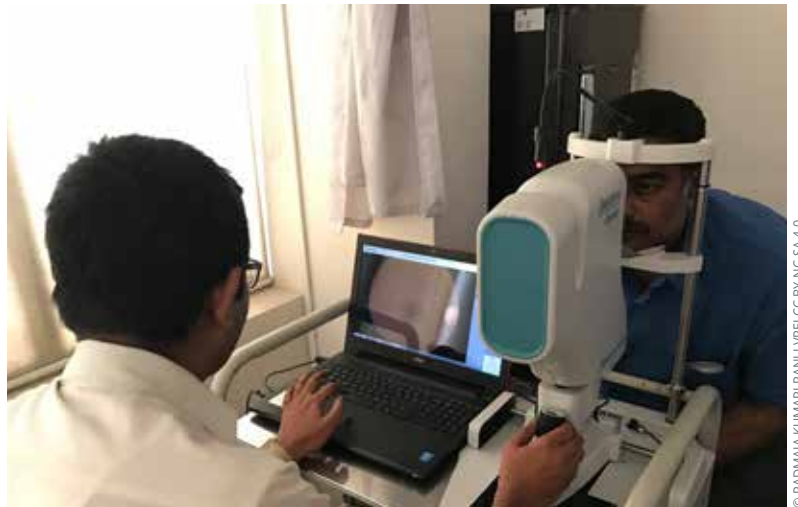
1. Prepare the patient

It is important to prepare the person by talking to them about what will happen, and why; this will help them to cooperate with you more fully. For example:

- Explain the reason for taking more than one photo of each eye and why they will be given dilation drops (if used).
- If using a camera with a flash, tell the person to expect a flash of light when the image is captured.
- If there is a target for them to look at, explain clearly what you want them to do, and why.

2. Consider pupil size

If a pupil is too small, the resulting images can be too dark and blurred to grade. For this reason many programmes include pupil dilation (by instilling drops of a mydriatic agent) in their DR screening guidelines. Recent technology advances include cameras that are able to take photographs without dilating the pupils, and these can be useful in field screening programmes where pupil dilation may not be practical.



Physician screening DR using table top camera. INDIA

If the person has difficulty focusing on a fixed point (for example, if they have poor vision or loss of vision in one eye, it may be useful to use an eye patch or eye occluder to cover the affected eye.

3. Position the patient correctly

When using a static camera, the person's position at the camera can affect the quality of the image. Ensure that they are seated in a comfortable position. The use of a height-adjustable chair or table will help you to position the person's chin and forehead correctly. Tell them to blink and then keep the eyes wide open until the image is taken. It may be necessary to hold up the eyelid; for example, in people with droopy eyelids. When using a hand-held camera, ensure that both the person and the photographer are in a comfortable position.

4. Keep the lens clean

Keep the camera lens free from anything that may obscure the image, such as eyelashes, dust, saliva droplets from speaking over the lens, or fingerprints – these cause some of the more common artefacts seen in retinal images, making them difficult to grade. Carefully clean the lens according to the manufacturer's instructions, taking care not to scratch it.

5. Avoid bright light

A room which is brightly lit may cause the image to appear over-exposed at the centre, and darker or opaque at the outer edges. It is therefore better to take the photographs in a darkened room.

Challenges

There are situations where, despite doing your best and taking all precautions, the images are still not good enough to confidently grade the level of diabetic retinopathy. One example is when patients have cataract or corneal opacities that obscure the view of the retina. These patients should be referred to the eye clinic and the images classified as ungradable. Ensure that these patients are followed up and/or are referred back for DR screening after surgery.



Charles Cleland
Clinical Research
Fellow: International
Centre for Eye
Health, London
School of Hygiene &
Tropical Medicine,
London, UK.

Considerations for storing and managing retinal images

Storing and managing retinal images – so that each one is linked to the correct patient – is essential.

The retina is the only tissue in the human body in which blood vessels can be directly visualised. Eye care professionals can therefore use retinal images to detect and diagnose a range of eye conditions, including diabetic retinopathy (DR).

Training screener/graders to take retinal images and grade them has streamlined DR screening, and many more patients living with diabetes are now screened for DR every year. The number of retinal images being taken, stored and exchanged between eye care practitioners and institutions is therefore increasing rapidly.

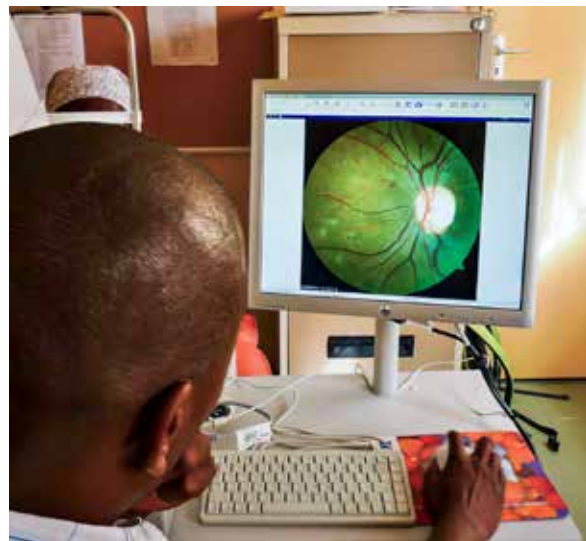
In a clinical setting, retinal images can be used to:

- Detect DR during screening
- Assess the progression of the disease (by comparing photographs taken during the annual screening visit with those taken the previous year)
- Assess the effects of treatment.

However, for images to be clinically useful, they must be linked to the correct patient information and stored securely and confidentially.

Labelling image files

Rename all image files using a unique patient identifier (such as a hospital ID) and the date the image was captured. To protect patient confidentiality, any information that could be used to identify the patient (name, date of birth) should be removed from the file name, particularly where the images are not stored in a secure patient database management system.



Label image files using a unique patient identifier and the date the image was taken.

Storage and back-up

A majority of retinal cameras have in-built storage capabilities and some have integrated patient database management systems. However, it is important to regularly back up images (ideally monthly) in case a camera malfunctions or is lost/stolen.

The process of backing up images varies between cameras but is straightforward; guidance is provided in manufacturers' manuals and websites.

There are several options for storage, including using centrally managed hospital servers or cloud storage services (depending on local approval). External hard drives, which have become much less expensive, are an alternative option, but these need to be stored securely, in a locked facility, where only authorised personnel have access.

How to organise retinal images

The images can be organised and stored by creating individual folders for each patient. The folders can be labelled using a unique patient identifier so a particular patient's images can easily be retrieved. Within the folders all the images relating to that particular patient can be stored with the image files labelled using the patient identifier and the date the image was captured.

Key tips

- Regularly back up images that are stored on cameras, e.g. either in a local server in the hospital if available or using external hard drives
- Link images to clinical information, e.g. by labelling the image file name with a unique patient identifier, such as a hospital ID
- Add the date the image was captured to the image file name
- Remove any personal identifiable information, such as a patient's name, from the image file name
- Use a filing system that allows you to easily retrieve an individual patient's images.

References

- 1 World Health Organization. Ethics and Governance of artificial intelligence for health: WHO guidance. 2021.
- 2 Ibrahim H, Liu X, Zariffa N, Morris AD, Denniston AK. Health data poverty: an assailable barrier to equitable digital health care. *Lancet Digit Health* 2021; 3(4): e260-e5.

Other reasons to carefully store and manage retinal images

Audit and research. Retinal images can be used for audit or research. For example, a programme may want to explore how effective DR screening has been, or find out which patients are more likely to have advanced disease. There are ethical considerations around this use of patient data, but generally the secondary analysis of anonymised clinical imaging data is acceptable, even if specific consent from the patient (which is often impossible) has not been taken.¹

Curation of local data sets for technology development. There have been many advances in the last few years in the development of artificial intelligence (AI) tools for DR screening. AI systems are trained on large numbers of retinal images that have already been screened by a qualified grader. The AI system 'learns' what each DR feature looks like, and is eventually able to grade images based on what it has seen.

The accuracy of an AI system depends on the images it has been shown. If it wasn't trained on images from specific low- or middle-income countries (LMICs), because of the shortage of local image datasets, the AI may not perform well in those populations. Systematically labelling and storing retinal image data is an important first step in developing retinal image datasets for LMICs. This will help to avoid 'health data poverty'² and reduce inequality in global health.



Covadonga Bascaran
 Clinical Research Fellow, London School of Hygiene and Tropical Medicine, UK.

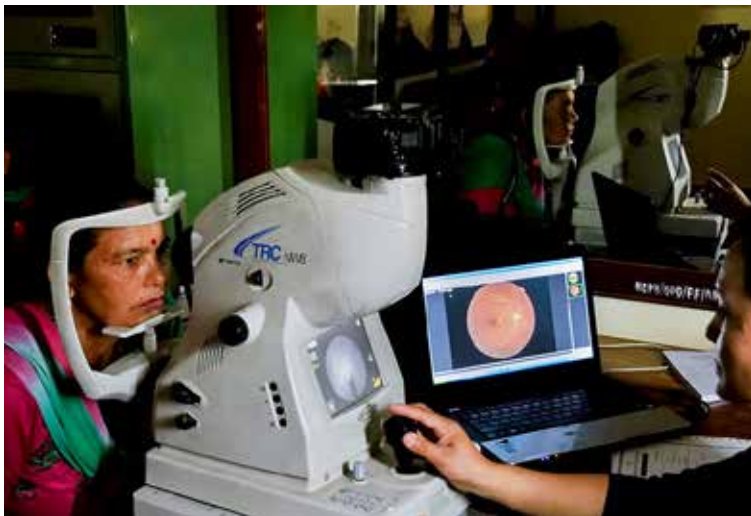Grading diabetic retinopathy: an introduction

The retina can be visualised to check for signs of diabetic retinopathy that require treatment.

In diabetes, elevated blood sugar levels damage the capillaries in the retina, resulting in a range of different, visible changes (Figure 1), collectively known as diabetic retinopathy (DR).

- **Weakened capillary walls** can result in microaneurysms. Further weakening causes capillaries to leak, causing retinal haemorrhages and the formation of hard exudates.
- **Blocked capillaries** starve the surrounding tissues of oxygen, which results in cotton wool spots and stimulates the production of vascular endothelial growth factor (VEGF), responsible for the growth of new vessels (neovascularisation).

People living with diabetes rarely notice changes in their vision during the early stages of DR. In order to detect early signs (such as cotton wool spots and microaneurysms), yearly retinal examinations are essential.

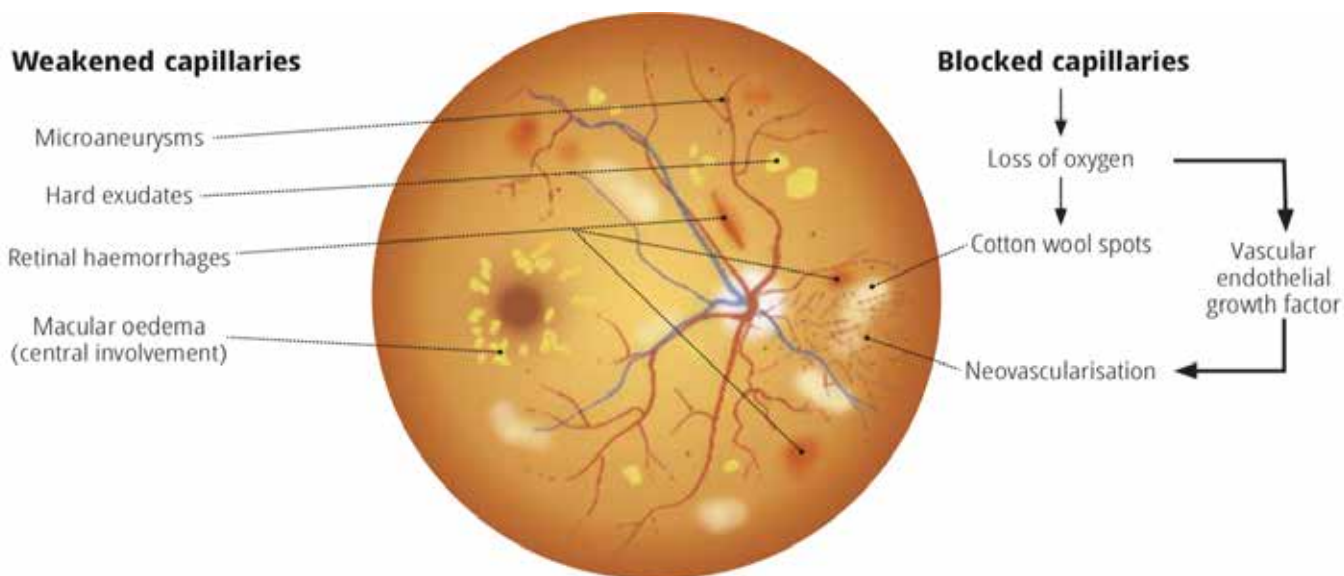


Diabetic retinopathy screening. NEPAL

The most common method of retinal screening is retinal photography. Trained graders examine the retinal images, looking for signs of DR. These signs are used to classify the level of disease severity and determine whether there is need to refer the patient for treatment. There are different classifications available, and each country or programme uses the one most appropriate to their setting.

The retinal features of DR recorded by the graders include: microaneurysms, hard exudates, retinal haemorrhages, cotton wool spots, venous changes, blot haemorrhages, intraretinal microvascular abnormalities, pre-retinal fibrosis, new vessels and tractional retinal detachment.

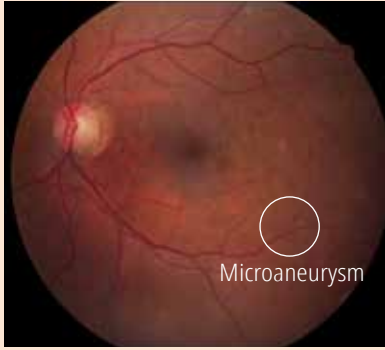
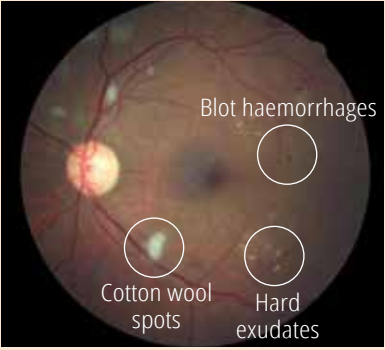
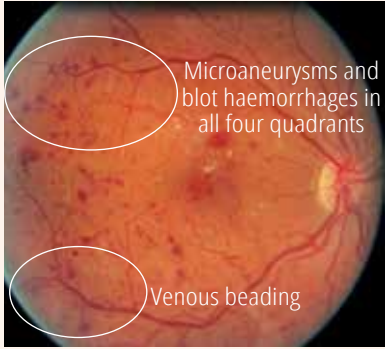
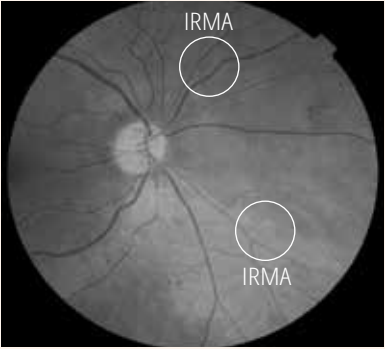
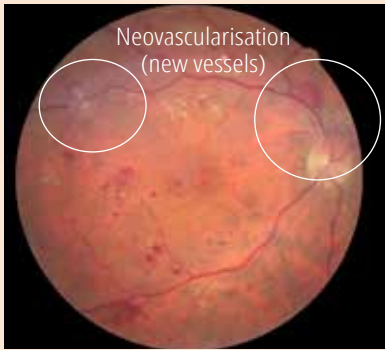
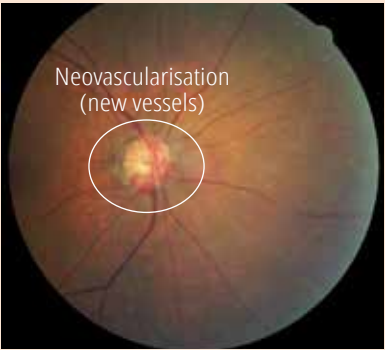


Figure 1 Signs of diabetic retinopathy.





Comparing the International Clinical Diabetic Retinopathy (ICDR) severity scale

Charles Cleland Clinical Research Fellow: International Centre for Eye Health, London School of Hygiene & Tropical Medicine. London, UK.

ICDR severity scale	Scottish grading protocol	English protocol	Example retinal images with labelled features	
Retinopathy grade				
No diabetic retinopathy (DR)	R0	No DR (R0)	Normal retina	
Mild non-proliferative diabetic retinopathy (NPDR) Microaneurysms only	R1 Microaneurysms or haemorrhages with or without hard exudates	Background DR (R1)	Mild NPDR	Moderate NPDR
Moderate NPDR 1 Any of the following: • microaneurysms • retinal dot or blot haemorrhages • hard exudates or cotton wool spots 2. No signs of severe NPDR	R2 4 or more blot haemorrhages in 1 hemifield only			
Severe NPDR 1 More than twenty intraretinal haemorrhages in all 4 quadrants 2 Definite venous beading in 2 or more quadrants 3 Prominent intraretinal microvascular abnormality (IRMA) in 1 or more quadrants 4 No signs of proliferative retinopathy	R3 4 or more blot haemorrhages in superior and inferior hemifields	Pre-proliferative DR (R2)	Severe NPDR	
				
Proliferative DR One or both of the following: • neovascularisation (new vessels) • vitreous/pre-retinal haemorrhage	R4	Proliferative DR (R3)	Proliferative DR	
				
Maculopathy grade				
No macular oedema No exudates or apparent retinal thickening within one disc diameter (DD) of the fovea	M0	M0	Normal macula	
Macular oedema Exudates or apparent thickening within 1 DD of the fovea	M1 Any lesions within 2 DD but more than 1 DD from the fovea	M1	Macular oedema	
	M2 Any lesions < 1 DD from the fovea			
Examples of maculopathy showing exudates within 1 disc diameter (DD) of the fovea				

DR: diabetic retinopathy, NPDR: non-proliferative diabetic retinopathy, IRMA: intraretinal microvascular abnormality, DD: disc diameter



Catherine Jamison

Senior Ophthalmic Image Analyst: Centre for Public Health, Queen's University Belfast, Belfast, UK.



Laura Cushley

Research Assistant: Centre for Public Health, Queen's University Belfast, Belfast, UK.



Katie Curran

Research Fellow: Centre for Public Health, Queen's University Belfast, Belfast, UK.



Tunde Peto

Professor of Clinical Ophthalmology: Centre for Public Health, Queen's University Belfast, Belfast, UK.

Grading images for diabetic retinopathy: tips and guidelines

Diabetic retinopathy screening relies on the accurate grading of retinal images so that patients can receive the care they need. Here is how.

This article was written as a short guide to grading retinal images for diabetic retinopathy (DR). It is mainly for people starting their grading journey, but it will also be helpful for experienced graders who want to improve upon their current techniques.

Tips for learning and quality control

DR screening relies on graders accurately identifying patients with DR, so graders must be trained according to the relevant guidelines and chosen grading classification. There must also be a system in place for quality assurance to ensure that the accuracy of grading is maintained.

The 'think out loud' approach

The 'think out loud' or 'think aloud' approach can be useful for training. When using this approach, both the expert grader and the trainee graders say out loud what they are observing and thinking when examining a fundus image for DR. When an **expert grader** does this in the presence of trainee graders, they are modelling the grading process and supporting the trainees to develop their own critical thinking skills. The expert grader can also stop and respond to questions.

When the **trainee graders** say out loud what they are seeing and thinking, this helps the expert grader to better understand their thinking processes and identify where improvements are needed. For example, a trainee grader may mistake exudates for drusen. If this happens, the expert grader can acknowledge the error and explain the differences between the two signs.

Remember: it is very important to work together within your team and learn from each other. Enjoy any teaching you can and remember there are always people who can help. Get experience – the more you grade, the better you will get, and your confidence will grow. So keep grading!

Quality assurance

Different levels of quality assurance can be used, depending on how well established a DR screening programme is. Smaller, opportunistic DR screening programmes could introduce internal checks; for example, a proportion of the images can be double checked by a second grader to ensure agreement.

More formal systems can be introduced as programmes develop and become more systematic. An example of this is the International Test and Training (iTAT) system ([bit.ly/iTAT-DR](#)). Registered graders receive a monthly set of images to grade and are given automated feedback on their performance.

The Diabetic Retinopathy Network (DR-NET) offers free access to the iTAT system to graders working in any of its 32 member programmes. Graders also have access to DR-NET online workshops and quarterly DR-NET 'Grading Grand Rounds', during which retinal images are shown and graded anonymously by the participating graders. The 'Grading Grand Rounds' also allows graders to meet and discuss pertinent issues. DR programmes in low- and middle-income countries can request to become members of the DR-NET, free of charge, by registering on [www.dr-network.org](#).

Tips for grading retinal images

Tip 1. Have a system

To be thorough and efficient as a grader, it is best to have a system when analysing a retinal image. Your system does not need to be the same as that of your fellow grader, provided that you examine all the key areas of the retina.

Using the same method every time makes it much less likely that you will forget to look at any one area.

We use the method shown in Figure 1:

Figure 1 An example of a systematic approach to grading.

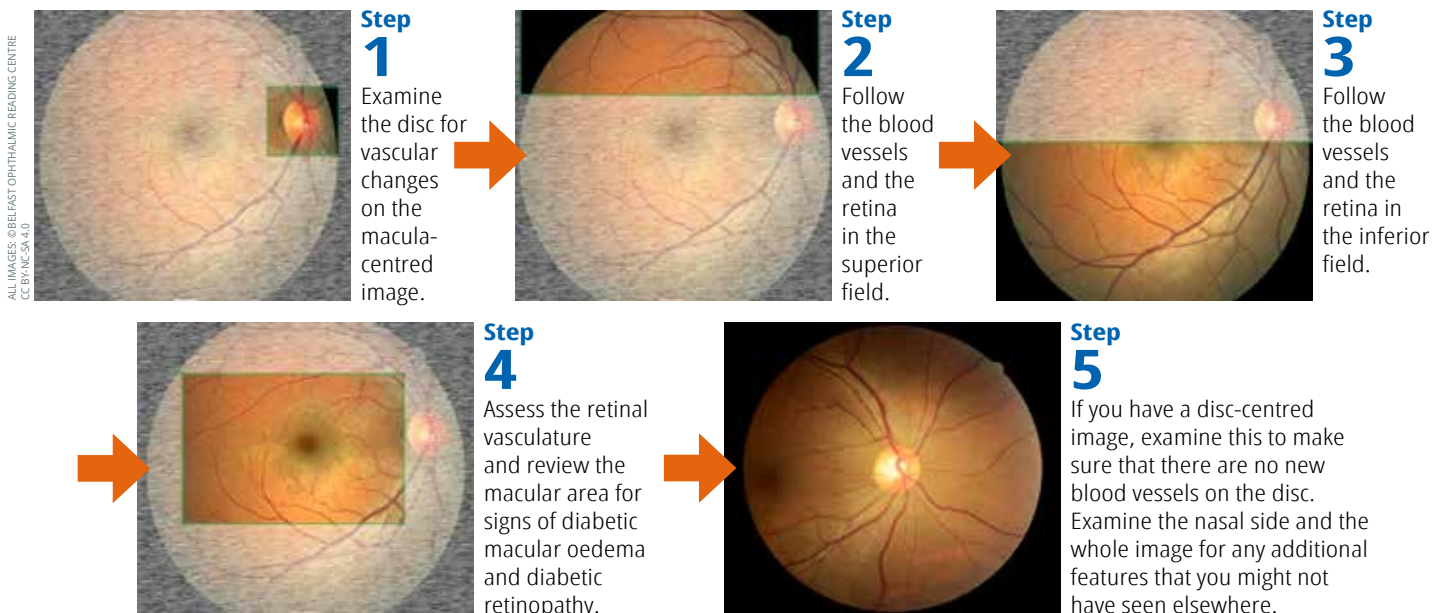
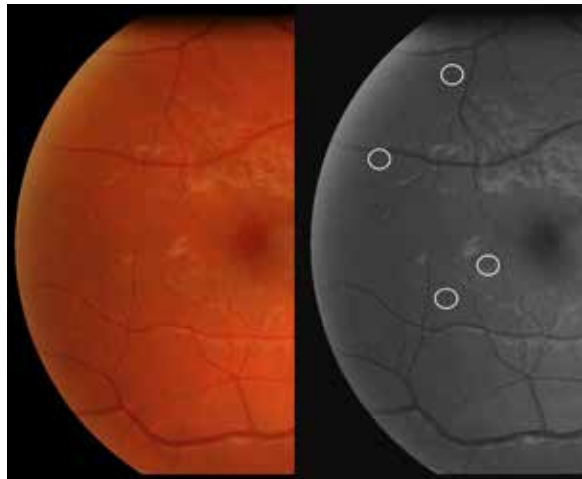

Figure 2

When viewing the image in black and white, microaneurysms can be seen.



© BELFAST OPHTHALMIC READING CENTRE CC BY-NC-SA 4.0

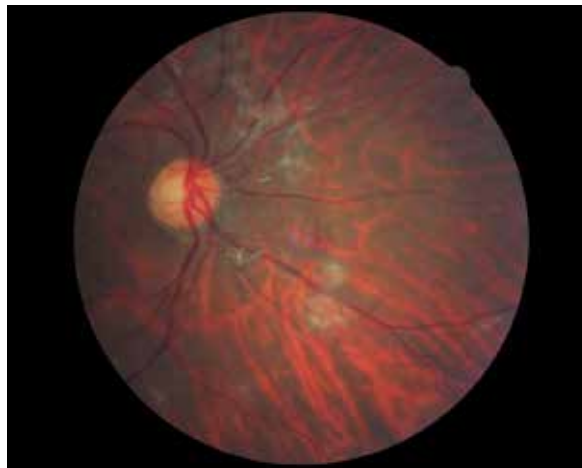
Tip 2. Use the red-free option

Red-free is a vital and helpful tool. Even as an experienced grader, an image may look like there is no pathology at all, but when red-free is applied a microaneurysm suddenly becomes apparent (Figure 2). Even when using ordinary image-viewing software to grade an image, it is usually possible to view an image red-free by turning the colour on the image down to 0 or by applying a black-and-white filter. If possible, red-free should always be used to double-check an image.

You can zoom in and magnify the image, but make sure that the features are still visible, and the image is not too pixelated. It is best practice to zoom out again and double-check that what you have seen on the magnified image is still visible on the normal-size image.

Figure 3

New vessels can be seen beyond the disc area.



© BELFAST OPHTHALMIC READING CENTRE CC BY-NC-SA 4.0

Tip 3. Look beyond the disc area

If you are using both macula-centred and disc-centred images, always examine the area nasal to, or beyond, the optic disc. This is an area where new vessels are often observed (Figure 3). Pathology can sometimes be seen in this area, even when the entire macula-centred image appears to be pathology free.

Tip 4. Evaluate the overall level of retinopathy

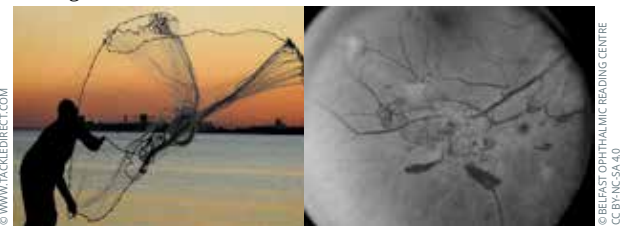Look at the overall level of retinopathy. If an eye gives you the impression of a moderate to severe level of DR, look carefully for new vessels or other proliferative features. Always evaluate the vasculature carefully. Note that there can be new vessels even when there are no other features of DR.

Tip 5. Know the difference between intraretinal microvascular abnormalities (IRMA) and new vessels

The most difficult decision for any grader, no matter how experienced, is the decision between IRMA and new vessels. Some hints include:

- New vessels might look like a traditional fishing net being cast out (Figure 4), whereas IRMA tend to be more angular and irregular in appearance.
- If they are on the disc, they are new vessels
- If they cross over the top of the retinal vessels, then they are new vessels

Figure 4 New vessels look like the casting-out of a fishing net.



© WWW.TAGGEDIRECT.COM

© BELFAST OPHTHALMIC READING CENTRE CC BY-NC-SA 4.0

Other pathologies that mimic DR

It is worth taking some time to study images of other pathologies which can be similar in appearance to some DR features. This avoids grading DR when it is not the case. Features which commonly are misinterpreted include:

- Drusen
- Fibrosis and myelinated nerve fibres
- Atrophic patches and laser scars
- Reflex
- Artefacts

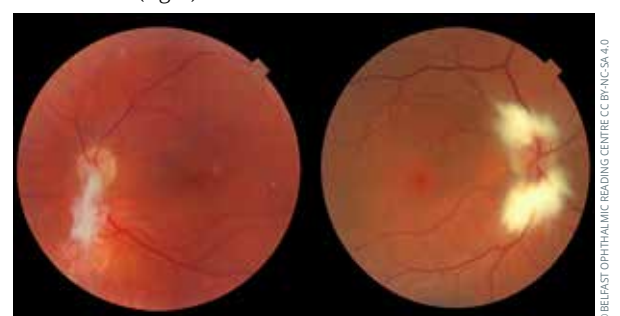
Drusen

Drusen are extracellular deposits found at the retinal pigment epithelium layer. Smaller drusen can be mistaken for hard exudates and larger drusen can be mistaken for cotton wool spots. See Table 1 for comparisons between the three signs.

Fibrosis and myelinated nerve fibres


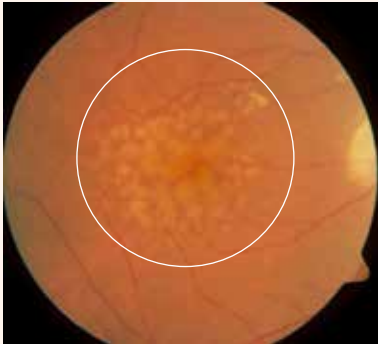

Fibrosis and myelinated nerve fibres tend to be found radiating out from the disc (Figure 5), although they can be found anywhere on the fundus. Fibrosis can have a whitish appearance, anywhere in the fundus, whereas myelinated nerve fibres are linear, streaky and follow along the lines of the nerve fibres. Myelinated nerve fibres are not a feature of DR, whereas fibrosis is a feature of proliferative retinopathy.

Figure 5 An example of fibrosis (left) and myelinated nerve fibres (right).



© BELFAST OPHTHALMIC READING CENTRE CC BY-NC-SA 4.0

Table 1 Differences between hard exudates, drusen and cotton wool spots.

	Hard exudates	Drusen	Cotton wool spots
			
Sign of DR?	Yes	No	Yes in the context of having other DR features as well
Shape and size	Irregular	Symmetrical	Larger than most drusen
Brightness & colour	Bright and clear	Dull, milky-white	Milky-white
Location	Anywhere in the retina	Predominately in the central macula, but may also be found in the posterior pole of the fundus	Anywhere in the retina
Depth	At the level of the vasculature	At the level of the retinal pigment epithelium (RPE) either exterior (towards the choroid) or interior (towards the retina) of the RPE	Nerve fibre layer of the retina

Atrophic patches and laser scars

Small patches of atrophy and laser scars (Figure 6) are areas where the outer layer of the retina has been destroyed either by laser treatment creating a scar, or by a disease that led to retinal death. Laser scars are likely to be smaller than atrophy patches and may be in an unnatural, grid-like pattern in the macula or in areas of the periphery. The appearance of the laser scar depends on the laser used and the time elapsed since the laser treatment was carried out. Laser scars are more likely to be peripheral and are unlikely to be very close to the fovea.

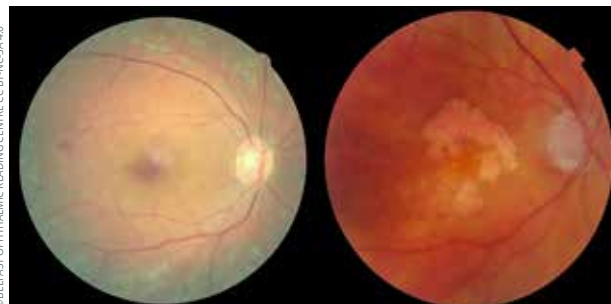


Figure 6 Examples of laser scars (left) and atrophy (right).

Reflex

Younger people will have a shiny reflex visible on the retina (Figure 7). This has a wispy, smoke-like appearance or sheen and is not pathology of any kind. Sometimes these reflexes can be mistaken for exudates.

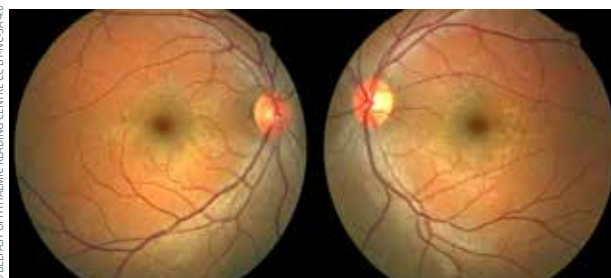

Figure 7 Examples of reflex.

Artefacts

Be aware of artefacts and how to spot them. Artefacts are caused by any object on the lens that may obscure the image (Figure 8, left), such as eyelashes, dust, saliva droplets from speaking over the lens, or fingerprints. Dirt on the camera appears as circular, greyish marks (Figure 8, right).

If you are unsure whether something is an artefact, look at the disc-centred image or images of the other eye. If the marks appear in the same location on any other image, then they are artefacts. However, if the marks move with the eye and appear on the same retinal location, then they are likely to be real changes.

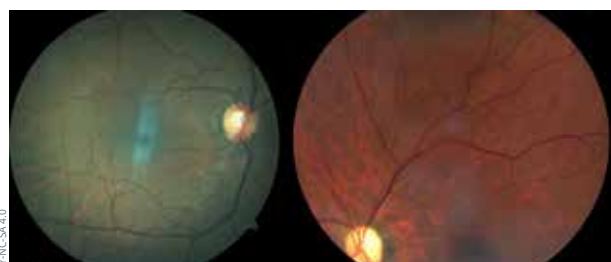

Figure 8 Examples of artefacts on a retinal image.



David Yorston
Consultant
Ophthalmologist,
Tennent Institute of
Ophthalmology,
Gartnavel Hospital,
Glasgow Scotland.

Understanding and managing sight-threatening diabetic retinopathy

Diabetic retinopathy can cause blindness. However, with prompt recognition and treatment, eye workers can prevent severe sight loss in most patients.

Ideally, we would prevent diabetic retinopathy (DR) using either primary prevention, by reducing the risk of Type 2 diabetes, or secondary prevention: managing diabetes so effectively that the risk of complications is reduced. Eye workers should use every opportunity to emphasise the importance of maintaining a healthy weight to prevent Type 2 diabetes, as well as achieving good control of blood sugar and blood pressure to reduce the risk of developing severe retinopathy. However, given that there are many millions of people with diabetes, we will have to manage established DR to minimise the risk of losing vision.

Early recognition and diagnosis of DR has a major impact on the effectiveness of treatment. Because the management of DR is mostly about preserving vision, rather than restoring sight, this means that the better the vision is when treatment is started, the better it will be when treatment is complete.

How does diabetic retinopathy develop?

Diabetes leads to loss of the pericytes – the cells that support the retinal capillaries. As these cells are lost, the capillaries start to leak. Normally, the cells of the retinal capillaries are connected by “tight junctions”. This means that they are impermeable, except to small molecules like water, glucose, oxygen, and carbon dioxide. The effect of this is to suck water out of the retina, so that, in a normal eye, the retina contains very little water outside of the retinal cells.

In patients with diabetes, the permeable capillaries allow larger molecules (e.g. proteins and lipids) to leak into the retina, resulting in hard exudates. These large molecules draw water out of the capillaries and the retina becomes swollen and waterlogged, or oedematous. If the retinal oedema involves the macula, it is known as **macular oedema** (see below). If this does not involve the fovea – the central portion of the macula – it will not affect the vision. However, if the fovea is involved, visual acuity will be reduced.

As the damage to the capillaries continues, they become blocked. This leads to inadequate blood supply (ischaemia). The ischaemic retina produces local growth factors to encourage new blood vessels to grow to compensate for the blocked capillaries. This is known as **proliferative diabetic retinopathy** (see below). Unfortunately, these new vessels do not grow in the retina, but on the back of the vitreous face. This leads to sheets of fibrovascular tissue attached to both the retina



Indirect laser delivery for diabetic retinopathy.

and the vitreous. As this fibrous tissue contracts, it tears the blood vessels, causing vitreous haemorrhage, and pulls on the retina, causing a traction retinal detachment.

Diabetic macular oedema

In high-income settings, diagnosis of macular oedema is made by optical coherence tomography (OCT). This uses low power lasers to create a cross-sectional image of the macula, and it is very easy to determine whether or not there is oedema at the fovea. In the absence of OCT, eye workers have to be a bit smarter! If the visual acuity is good (6/12 or better), it is unlikely there is significant macular oedema. If the visual acuity is reduced, then a careful examination of the macula, with a well-dilated pupil and a 60D lens, will usually show swelling, with cysts in the retina. There are also likely to be exudates, small intraretinal haemorrhages, and microaneurysms within 1 disc diameter of the fovea.

The best management of macular oedema is regular injections of an anti-VEGF drug. This treatment has been shown to be more effective than laser in multiple clinical trials. A course of injections improves vision by an average of 10 letters after one year. In comparison, laser treatment may preserve visual acuity, but will not improve it.

Proliferative diabetic retinopathy

New vessels are usually found on the optic disc or in the mid-peripheral retina, a little beyond the vascular arcades.

They can be detected by carefully examining the retina. Red-free light makes the abnormal vessels easier to

detect. The best way of finding these new vessels is with a wide field camera, but these are not always available. Fortunately, new vessels can be treated. If they are at a relatively early stage, with no vitreous haemorrhage or traction retinal detachment, laser treatment will make them shrivel up, which greatly reduces the risk of vision loss. Laser treatment is not directed at the new vessels themselves, but at the peripheral retina. This reduces the production of the growth factors, and the new vessels regress.

Laser treatment

Laser treatment can be delivered at a slit lamp, or using an indirect ophthalmoscope. Slit lamp laser is quick, but it requires specialist lenses and a delivery system – which is expensive. Laser treatment can also be delivered using an indirect ophthalmoscope, if available, and if the ophthalmologist has the skills to use it. It does not require any additional equipment apart from the laser itself. In this procedure, the patient is lying down and can be given a local anaesthetic block, which makes it easier to do a lot of laser in one session.

Complete laser treatment requires between 2,000 and 3,000 laser burns using a 200-micron laser. Ideally, treatment should be separated into two sessions, about 4–8 weeks apart. This is safer than doing all the laser at once. Too much laser in a short time can lead to rapid fibrosis and contraction of the fibrovascular membranes and may cause a traction detachment.

Anti-VEGF injections vs laser

Injections of anti-VEGF drugs also cause rapid regression of new vessels. Some trials have shown that the visual results of regular anti-VEGF injections are slightly better than laser treatment. However, laser usually has to be delivered only twice – and it can be done in a single treatment session – but anti-VEGF drugs have to be given every 4–8 weeks, may need to be continued indefinitely, and ideally require an OCT machine to help plan the treatment. Lasers are expensive, and most can only be in one place at a time. They have a finite life expectancy, so even if you have a laser, you may need to replace it after 10 years. Although anti-VEGF drugs are costly, they can potentially be given by a trained nurse, which is already happening in high-income settings, and only requires a clean room. In a low-income setting, the cost of buying a laser is borne by the facility, while the patient has to pay for the cost of the anti-VEGF drugs.

As the cost of anti-VEGF drugs decreases, their role in LMICs is likely to become more prominent. Any clinic that does cataract surgery can give anti-VEGF. In high-income settings, where lasers are widely available, laser remains the treatment of choice for diabetic new vessels, and anti-VEGF is used if there is concurrent macular oedema.

Vitreoretinal surgery

Despite adequate laser or anti-VEGF treatment, some patients will lose vision because of vitreous haemorrhage or traction detachment of the retina. The best chance of restoring their vision is a vitrectomy. This is complex surgery in which a small (usually 25G) vitreous cutter is

used to dissect the vitreous and associated fibrovascular tissue from the retina. This removes any haemorrhage, leaving a clear visual axis, and releases traction on the retina, allowing the retina to re-attach.

The results of vitrectomy for DR have improved greatly over the past two decades. This is partly due to improved technology, as the latest vitrectomy machines are safer. Another important advance is the use of preoperative anti-VEGF injections. This is particularly important in low-resource countries where patients may not have had good laser treatment before surgery. A study in Tanzania showed that pre-treatment with anti-VEGF doubled the probability of restoring sight in eyes blinded by DR. If anti-VEGF is given preoperatively, it should be between 3 and 10 days before surgery. It needs a few days to take effect, but a longer period risks excessive fibrosis and contraction of the membranes, leading to a worse traction detachment.

Who should be referred?

Because vitrectomy requires complex and costly equipment, only a few centres will be able to offer it. Most eye workers will not need to know the details of the operation, but they do need to know who to refer. The two main indications for surgery are:

- Non-clearing vitreous haemorrhage
- Traction retinal detachment.

Recent haemorrhages (less than one month in duration) can be left to clear, as many will improve with time. If the patient is blind in the other eye, earlier referral and surgery may be indicated. Mild haemorrhages (visual acuity better than 6/36) can also be left, as they will usually clear. Patients with dense haemorrhages, that have not cleared in more than a month, should be considered for vitrectomy.

Traction detachment affecting the macula needs urgent repair, and should be referred immediately. If the detachment is outside the vascular arcades, surgery is not needed. Traction detachments close to the macula, but with good vision, may need surgery. If the patient had laser treatment years ago, the traction is unlikely to get worse, however, if the laser treatment started just a few months ago, the traction detachment is likely to increase, and vitrectomy may be indicated.

Looking to the future

A decade ago, DR was the leading cause of blindness in people of working age in some high-income countries, like the UK. Thanks to improvements in early detection and management of DR, ophthalmologists in the UK can now assure new patients with retinopathy that – provided they attend the clinic – there is very little risk that they will become blind because of their diabetes.

In low-resource, settings, diabetes is rapidly increasing, and diabetic retinopathy will become an important cause of visual impairment. Although most low- and middle-income countries do not yet have the resources to implement a nationwide screening programme, we need to start putting in place the systems for early detection and treatment now, so that these can be the foundations for even more effective programmes in the future.

“Early recognition and diagnosis of DR has a major impact on the effectiveness of treatment.”



Ismael Cordero
Clinical Engineer,
Philadelphia,
USA.

Caring for a retinal camera

Maintenance and care will prolong the life of this expensive item.

Retinal cameras, also known as fundus cameras, are used to take pictures of the back of the eye.

A retinal camera consists of a specialised microscope with an integrated or attached camera. There are two main types: table top (Figure 1) and hand held.

Daily care

At the start of each screening session, check the objective lens to make sure it is free of dirt. Clean if needed, following the manufacturer's instructions.

After each patient, clean and disinfect the parts of the camera that were in contact with the patient, mainly the forehead rest and chin rest. This reduces the risk of spreading infections between patients.

At the end of each screening session

- Turn off the instrument
- Clean the camera body and objective lens
- Cover the objective lens with the protective lens cap
- Cover the instrument with its dust cover. **Note:** never replace the dust cover when the illumination is on.

Storage

If you intend not to use the camera for a long period of time, take the plug out of the socket and replace the lens cap and dust cover. Keep the instrument in a

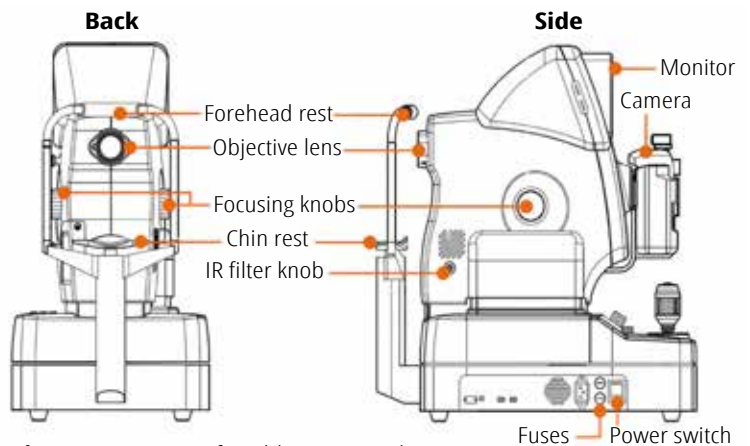


Figure 1 Diagram of a table-top retinal camera.

dry and well-ventilated area; this will help to prevent fungal growth.

Maintenance tips

- When replacing bulbs, do not touch them with your bare hands. Touching bulbs may shorten their life and reduce the amount of light they emit.
- When replacing any fuses, make sure that the instrument is turned off and unplugged. Wait at least 5 minutes for the power supply to discharge.
- Have the instrument checked and maintained regularly by the vendor at least once every two years to confirm its performance and safety. Consult your dealer for details and the cost of the inspection.

Important

Before you start any cleaning, disinfection, or maintenance activities, consult the instructions for the specific model of retinal camera. The use of improper cleaning agents and procedures may void the warranty and degrade the equipment.

ARTIFICIAL INTELLIGENCE



Charles Cleland
Clinical Research
Fellow:
International Centre
for Eye Health,
London School of
Hygiene
& Tropical
Medicine, London,
UK.

Artificial intelligence in DR screening

AI is already being used in some diabetic retinopathy screening programmes. How does it work, and how will it affect the role of DR graders?

Artificial intelligence software can be used to grade diabetic retinopathy (DR) images. There are several commercially available AI tools for DR screening that have been proven to be just as accurate as human graders in detecting DR.¹

In practice, a retinal image taken with a camera is submitted to the AI software. The software can be an integrated part of the camera itself, or it can function as a separate application on a computer or laptop which is connected to the camera. The AI system automatically grades the image and gives a result, typically in 30 seconds or less.

The majority of AI systems are based in the 'cloud' (on geographically remote servers), so they must be connected to the internet to produce a report.

Most AI systems give a simple response, such as "refer" or "don't refer", or they tell the user that the image is too

low in quality and therefore ungradable. Some systems give a more detailed grade for DR, usually according to the International Clinical Diabetic Retinopathy (ICDR) severity scale.

It is very unlikely that AI will completely replace the role of DR graders in the near future. In part, this is due to the cost of cameras, software, and other technologies, as well as ethical and legal issues.³ In addition, human graders are also needed to provide quality assurance for a programme involving AI. Patients enrolled in a screening programme need to be counselled at the point of screening by an appropriately trained staff member whose role it is to explain the results and the next steps to take.

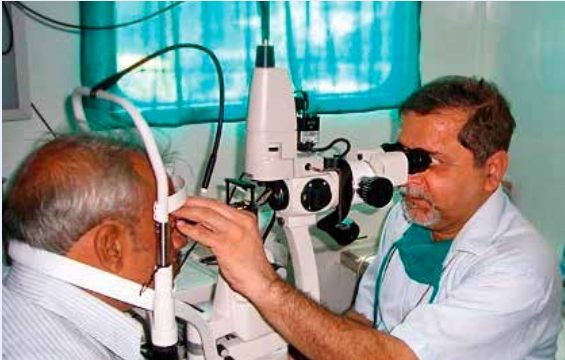Overall, AI is likely to become a tool that will assist DR programmes and graders to deliver effective and patient-centred DR programmes, rather than becoming a replacement for graders.

References

- 1 Grzybowski A, Brona P, Lim G, et al. Artificial intelligence for diabetic retinopathy screening: a review. *Eye*. 2020; 34(3): 451–60.
- 2 Mathenge WC. Artificial intelligence for diabetic retinopathy screening in Africa. *Lancet Digit Health*. 2019;1(1):e6–e7.

Key community eye health messages

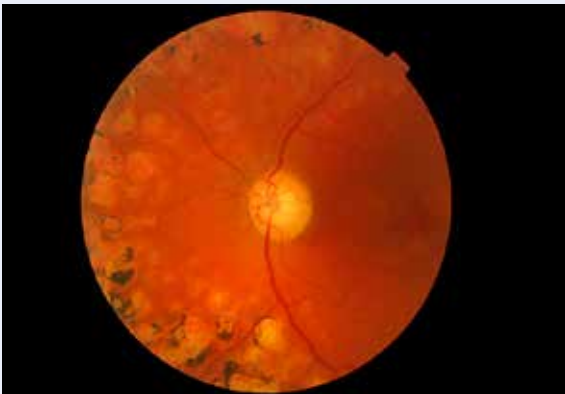Diabetic retinopathy and its risk factors



© PROJECT NAVANTARA CC BY-NC-SA 4.0

- Diabetes increases the risk of various eye diseases, including diabetic retinopathy (DR), which affects the blood vessels within the retina.
- DR can affect both eyes and if left untreated, may cause vision loss.
- Risk factors for developing DR include poorly controlled blood sugar levels, high blood pressure, and high cholesterol levels.

Progression of diabetic retinopathy



© CEHJ CC BY-NC-SA 4.0

- Over time, uncontrolled blood sugar can lead to abnormal growth or blockage of retinal blood vessels.
- Abnormal vessel growth due to reduced oxygen flow can result in **retinal scarring and detachment**.
- Fluid accumulation and swelling in the macula can lead to **blurred vision**.
- In later stages, irreversible damage causes **blindness**.

Screening and intervention in diabetic retinopathy



© LVPEI, INDIA CC BY-NC-SA 4.0

- DR often has no early symptoms, so many people with diabetes may not notice changes in their vision.
- The disease can progress unnoticed until it reaches advanced stages, potentially causing irreversible damage and blindness.
- Yearly retinal examinations are crucial to detect the early signs of DR, allowing for timely intervention.
- Treatment usually maintains vision but does not restore vision that has already been lost.
- People at risk of vision loss due to DR can receive treatments such as laser therapy, anti-VEGF treatment, or vitreoretinal surgery. The choice of treatment depends on the stage of the disease and other individual factors.