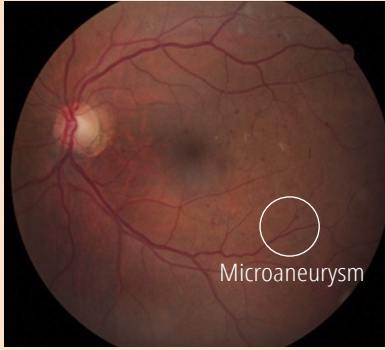
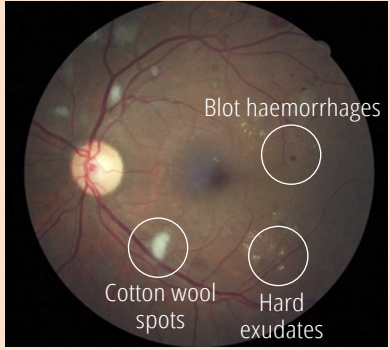
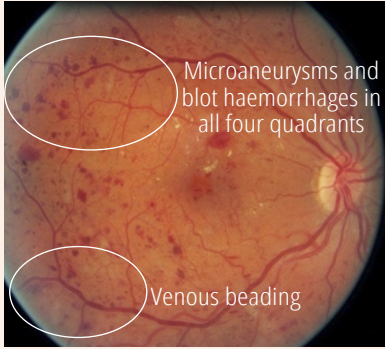
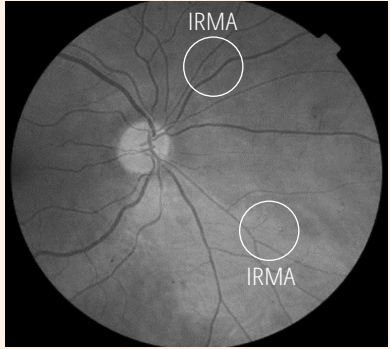
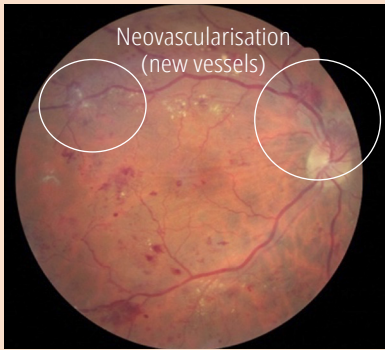
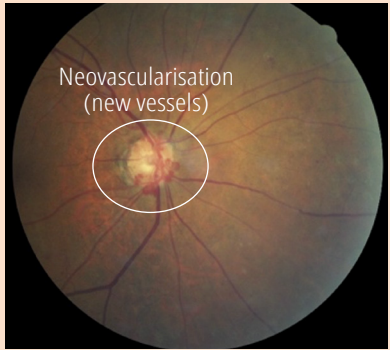






# Comparing the International Clinical Diabetic Retinopathy (ICDR) severity scale

**Charles Cleland** Clinical Research Fellow: International Centre for Eye Health, London School of Hygiene & Tropical Medicine. London, UK.

ICDR severity scale	Scottish grading protocol	English protocol	Example retinal images with labelled features	
<b>Retinopathy grade</b>				
<b>No diabetic retinopathy (DR)</b>	<b>R0</b>	<b>No DR (R0)</b>	<b>Normal retina</b>	
<b>Mild non-proliferative diabetic retinopathy (NPDR)</b> Microaneurysms only	<b>R1</b> Microaneurysms or haemorrhages with or without hard exudates	<b>Background DR (R1)</b>	<b>Mild NPDR</b>	<b>Moderate NPDR</b>
<b>Moderate NPDR</b> 1 Any of the following: • microaneurysms • retinal dot or blot haemorrhages • hard exudates or cotton wool spots 2. No signs of severe NPDR	<b>R2</b> 4 or more blot haemorrhages in 1 hemifield only			
<b>Severe NPDR</b> 1 More than twenty intraretinal haemorrhages in all 4 quadrants 2 Definite venous beading in 2 or more quadrants 3 Prominent intraretinal microvascular abnormality (IRMA) in 1 or more quadrants 4 No signs of proliferative retinopathy	<b>R3</b> 4 or more blot haemorrhages in superior and inferior hemifields	<b>Pre-proliferative DR (R2)</b>	<b>Severe NPDR</b>	
				
<b>Proliferative DR</b> One or both of the following: • neovascularisation (new vessels) • vitreous/pre-retinal haemorrhage	<b>R4</b>	<b>Proliferative DR (R3)</b>	<b>Proliferative DR</b>	
				
<b>Maculopathy grade</b>				
<b>No macular oedema</b> No exudates or apparent retinal thickening within one disc diameter (DD) of the fovea	<b>M0</b>	<b>M0</b>	<b>Normal macula</b>	
<b>Macular oedema</b> Exudates or apparent thickening within 1 DD of the fovea	<b>M1</b> Any lesions within 2 DD but more than 1 DD from the fovea	<b>M1</b>	<b>Macular oedema</b>	
	<b>M2</b> Any lesions < 1 DD from the fovea			
Examples of maculopathy showing exudates within 1 disc diameter (DD) of the fovea				

DR: diabetic retinopathy, NPDR: non-proliferative diabetic retinopathy, IRMA: intraretinal microvascular abnormality, DD: disc diameter