

# Community Eye Health Journal

VOLUME 36 • NUMBER 121 • 2023 South Asia Edition

Don't miss out

Download the free  
Community Eye Health  
Journal app today!  
[bit.ly/CEHJ-app](https://bit.ly/CEHJ-app)



SCAN ME



Good vision during infancy and early childhood is vital for normal development, including social development. [INNOVA](#)

©ARAVIND EYE CARE CC BY-NC-SA 4.0

## Improving eye care for children

*I knew as soon as my son was born there was something wrong with his eyes. Why child health must include eye health.*



**Aeesha Malik**

Clinical Assistant Professor and Consultant Paediatric Ophthalmic Surgeon: International Centre for Eye Health, London, UK.



**Clare Gilbert**

Professor of International Eye Health: International Centre for Eye Health, London School of Hygiene & Tropical Medicine, London, UK.

Ashura Hemed knew soon after her son, Shadrack, was born that there was something wrong with his eyes. They looked larger, were watery, and he hardly ever opened them. Ashura had visited the local primary level child health clinic five times over three months. Not knowing how to examine Shadrack, or what to look for, the child health care workers either ignored Ashura's questions and concerns, or gave her antibiotic eye drops that had no impact on Shadrack's condition.

Shadrack was lucky – his family happened to live near Dar es Salaam, the largest city in Tanzania, which has child eye care facilities. His determined mother took him to an eye department where he was diagnosed with congenital glaucoma. He is now doing well and is being followed up after surgery.

Shadrack was one of the lucky ones – if he hadn't been correctly diagnosed and treated in time, he would

have grown up blind or severely visually impaired.

Parents all over the world face similar problems to Shadrack and his family. Primary eye care services for children are limited or non-existent in many low-income settings, particularly in rural areas, away from big cities. This means that children often present late to eye care services – sometimes many months, or even years after their parent or carer first noticed the problem. Delayed treatment can lead to worse vision and developmental outcomes than if treatment had been given on time. In the case of retinoblastoma (a form of eye cancer), delays can result in the death of the child.

Children are particularly vulnerable to the consequences of inadequate eye care. Good vision is needed from birth until the age of seven years to ensure that children's brains develop the visual pathways that will lead to healthy adult vision. Anything that obstructs



## About this issue

Children need good vision from birth until the age of seven years to ensure that their brains develop the visual pathways that will lead to healthy adult vision. Anything that obstructs their vision during this crucial time can result in lifelong visual impairment or blindness, as well as delays to their overall physical, mental, and social development; this is the case even if their eye condition is treated when they are older. The articles in this issue are designed to be as accessible as possible, so you can use them to refresh your own knowledge or adapt them for teaching.

## Contents

- 1 Improving eye care for children**  
Aeesha Malik and Clare Gilbert
- 4 Common eye conditions in children: care and referral at primary level**  
Sucheta Kulkarni and Dupe Ademola-Popoola
- 8 Detecting vision problems in children**  
P Vijayalakshmi
- 10 Congenital glaucoma: the 'not-so-silent' thief of sight in children**  
Vera Adobebe Essuman and Vera Mawusime Beyou
- 13 Preseptal and orbital cellulitis: how to identify and treat these conditions – and save lives**  
Rilwan Muhammad and Fatima Kyari
- 15 Recognising and managing bilateral cataracts in children**  
Sarah Sitati
- 18 Corneal ulcers in children**  
Clare Gilbert
- 20 Cerebral visual impairment**  
Richard Bowman and P Vijayalakshmi
- 23 New World Health Organization guidelines**
- 24 Important messages for eye health in babies and young children**  
Aeesha Malik

their vision during this crucial time, such as cataract or corneal scarring, can result in lifelong visual impairment or blindness, as well as delays to their overall physical, mental, and social development. This is the case even if their eye condition is treated when they are older.

### Improving eye care services for children

To address the critical issue of children presenting late, there needs to be routine screening of children, at primary or community level, to detect eye conditions in time. However, there are only a few screening guidelines for eye conditions in children, and most are for high-income countries.<sup>1</sup> One notable exception is India's guideline on universal eye screening in newborns, which includes retinopathy of prematurity.<sup>2</sup>

There has been some progress. Recently, the World Health Organization (WHO) included eye screening as part of the general examination of all newborns.<sup>3,4</sup> However, screening guidelines are also needed for other conditions and in older children. Personnel who care for children at primary, secondary, and tertiary levels must receive the necessary training to detect, refer, and/or diagnose and manage children who need help.

Children under the age of 5 years frequently – perhaps more so than at any other time in their lives – visit primary health care facilities, e.g. for vaccinations, growth monitoring, or when they are ill. Personnel working in primary health clinics are, therefore, very well placed to detect children with eye conditions and provide initial care, referring them if needed.

In 1995, WHO and the United Nations Children's Fund (UNICEF) jointly launched a global programme called the Integrated Management of Childhood Illness; when newborns were added, this became known as the Integrated Management of Newborn and Childhood Illnesses (IMNCI) programme. IMNCI contains modules for the major conditions affecting children, such as fever or malnutrition, and each module has an algorithm that helps workers determine the severity of the condition and tells them how to manage it at primary level. More than one hundred countries have implemented the IMNCI programme to date. Although there is a module for ear problems, there is not yet one for eye problems.

**Community Eye Health Journal**  
VOLUME 36 • NUMBER 121 • 2023  
South Asia Edition



INTERNATIONAL  
CENTRE FOR  
EYE HEALTH



LONDON SCHOOL OF  
HYGIENE & TROPICAL  
MEDICINE



**Editor-in-Chief**  
Elmien Wolvaardt  
editor@cehjournal.org

**Editor, South Asia edition**  
Kriti Shukla  
editor@cehjsouthasia.org

**Editorial committee**  
Simon Arunga  
João M Furtado  
Clare Gilbert  
Esmael Habtamu  
Fatima Kyari  
Ciku Mathenge  
Nyawira Mwange  
GVS Murthy  
Heiko Philippin  
Thulasiraj Ravilla  
Serge Resnikoff  
Jude Stern  
Sumrana Yasmin  
David Yorston

**Regional consultants**  
Hugh Taylor (WPR)  
Leshan Tan (WPR)  
GVS Murthy (SEAR)  
R Thulsiraj (SEAR)  
Babar Qureshi (EMR)  
Mansur Rabiou (EMR)  
Hannah Faal (AFR)  
Kovin Naidoo (AFR)  
Wanjiku Mathenge (AFR)  
Ian Murdoch (EUR)  
Janos Nemeth (EUR)  
Van Lansingh (AMR)  
Andrea Zin (AMR)

**Proof reading** Kriti Shukla  
**Designing** V Arun Kumar  
**Printing** Pragati Printers

**Consulting editor for issue 121**  
Aeesha Malik  
Clare Gilbert

**South Asia Editorial Board**  
Victor Hu  
Damodar Bachani  
Thulasiraj Ravilla  
Rajiv Raman  
Rohit C Khanna  
Asim Sil  
GVS Murthy

**South Asia Advisory Committee**  
Victor Hu BR Shamanna  
Hans Limburg K Vishwanath  
Elizabeth Kurian M Babar Qureshi  
Sara Varughese Prabhat Piyasena  
Muhit Mohammad Noopur Gupta  
Sanduk Ruit Reeta Gurung

## Tanzania: showing what is possible

During a pilot study in Tanzania, an IMNCI module for eye problems was developed in collaboration with the ministry of health.<sup>4</sup> After successful completion of the pilot study, which demonstrated that eye health could be included in child health services in a way that was practical and acceptable to primary health care workers,<sup>4</sup> the module was formally included in the national IMNCI policy. This resulted in more than 3,500 primary health care workers being trained in eye care. According to data from the ministry of health, these health workers see an average of 5.8 million children annually, potentially identifying nearly 250,000 children with eye problems every year.

The Tanzanian experience shows that it is possible for policy change to take place at national level, and for eye health to be included in a national child health strategy. This model can be applied in other countries, especially in the more than one hundred countries where IMNCI is already in place. More advocacy may be needed at WHO level for the inclusion of an eye care module in IMNCI; this may help to encourage more countries to follow Tanzania's example.

Enabling good vision in early childhood is very important as it allows a child to develop normally and reach their full potential in every area of their life. Improving detection, referral, and treatment of eye conditions in children is therefore in line with a recent shift in global child health policies: from an emphasis on how to help children 'survive,' to a focus on how children can 'thrive.' This provides a major

## Useful websites

The Global Child Eye Health Consortium. <https://tinyurl.com/y7bexr5>  
IMNCI project video, including the case study in this article:

<https://tinyurl.com/sbupb6kf>

IMNCI training videos: <https://tinyurl.com/bpamvcmt>

Arclight training videos: <http://tinyurl.com/CEHJ-arclight>

IAPB School eye health guidelines: <https://tinyurl.com/ypnja65y>

opportunity for the inclusion of eye health in IMNCI and other national and global child health policies for young children. Once policies are in place, appropriate training and equipment for the local context will also be needed.

Eye care providers on their own cannot solve the problem of child eye health. We need to reach out to those making child health policies and running child health programmes to ensure eye health is integrated into these policies and programmes. One possible step is to advocate for the inclusion of eye care into IMNCI programmes in your own country, using the Tanzania case study as evidence and a model. Another helpful step is to refresh your own knowledge of child eye care and share this with others. The articles in this issue were designed to be as accessible as possible, to as wide an audience as possible, so they can be easily used and/or adapted by those who teach others.

By working together with others who care for children, we can ensure that no child becomes, or remains, needlessly blind.

## References

- 1 Malik AN, Evans JR, Gupta S, Mariotti S, Gordon I, Bowman R, Gilbert C. Universal newborn eye screening: a systematic review of the literature and review of international guidelines. *J Glob Health*. 2022 Oct 21;12:12003.
- 2 Newborn screening guidelines for India. <https://tinyurl.com/3z5c9sdp>
- 3 World Health Organization. WHO recommendations on maternal and newborn care for a positive postnatal experience. <https://tinyurl.com/WHOnewb>
- 4 Malik ANJ, Mafwiri M, Gilbert CE. Integrating Primary Eye Care into Global Child Health Policies. *Archives of Disease in Childhood* 2018; 103 (2): 176-180
- 5 Malik ANJ, Mafwiri M, Gilbert CE, Kim MJ, and Schellenberg J. Integrating eye health training into the primary child healthcare programme in Tanzania: a pre- training and post-training study *BMJ Paediatr Open*. 2020; 4(1): e000629.

## Subscribe

Visit <https://bit.ly/3uwMvf5>

## Address for subscriptions

Community Eye Health Journal South Asia, Indian Institute of Public Health, Exit No: 17, Survey No 384, Towards, Himayat Sagar Main Road, near Outer Ring Road, Rajendra Nagar, Hyderabad, Telangana 500030, India.

Tel +91-40-49006000

Email [editor@cehjsouthasia.org](mailto:editor@cehjsouthasia.org)

## Correspondence articles

We accept submissions of 800 words about readers' experiences in eye health. Contact:

[editor@cehjsouthasia.org](mailto:editor@cehjsouthasia.org)

Published by the International Centre for Eye Health, London School of Hygiene & Tropical Medicine.

Unless otherwise stated, authors share copyright for articles with the Community Eye Health Journal. Illustrators and photographers retain copyright for images published in the journal.

Unless otherwise stated, journal content is licensed under a Creative Commons Attribution-NonCommercial (CC BY-NC) license which permits unrestricted use, distribution, and reproduction in any medium for non-commercial purposes, provided that the copyright holders are acknowledged.

ISSN 0953-6833

## Disclaimer

Signed articles are the responsibility of the named authors alone and do not necessarily reflect the views of the London School of Hygiene & Tropical Medicine (the School). Although every effort is made to ensure accuracy, the School does not warrant that the information contained in this publication is complete and correct and shall not be liable for any damages incurred as a result of its use.

The mention of specific companies or of certain manufacturers' products does not imply that they are endorsed or recommended by the School in preference to others of a similar nature that are not mentioned. The School does not endorse or recommend products or services for which you may view advertisements in this Journal.

The *Community Eye Health Journal* is supported by:



South Asia Edition supported by:

TIJSEN  
FOUNDATION







**Sucheta Kulkarni**

Senior Consultant:  
PBMA's H. V. Desai  
Eye Care Institute,  
Department of  
Ophthalmology,  
Pune, India



**Dupe Ademola-Popoola**

Professor of  
Ophthalmology:  
Paediatric, Strabismus  
and Ophthalmic  
Oncology, University  
of Ilorin & University  
of Ilorin Teaching  
Hospital, Ilorin,  
Nigeria.

# Common eye conditions in children: care and referral at primary level

Believe parents and caregivers when they say there is something wrong with their child's eye(s) or vision. As some conditions are blinding if not diagnosed and managed promptly, refer the child if you are in any doubt.



Believe parents when they say there is something wrong with their child's eyes.  
TANZANIA

When a child presents with an eye problem, it is important to listen carefully to what the parent or caregiver says about what they have noticed, and to believe them when they say there is something wrong with their child's eyes or vision – they are nearly always right.

In this article, we discuss the most common eye conditions in children. These can be managed at community or primary level by either treating the child, or referring them to the nearest hospital with an ophthalmologist. If you need to refer a child, explain the level of urgency to the parent or caregiver and check that they understand where to go and when they must be there.

One of the first things you will notice about a child is their age; this is an important clue when finding out what might be wrong with their eyes. We have therefore listed the common eye conditions by the age they most commonly occur, starting with newborns and ending with older children and adolescents.

## A newborn baby with profuse discharge

During birth, a baby's eyes can be infected by organisms present in the birth canal. Two organisms that have the most severe consequences for the baby, and therefore require urgent treatment, are *Neisseria gonorrhoea* (the organism which causes gonorrhoea) and *Chlamydia trachomatis* (responsible for chlamydia).

If the mother has gonorrhoea, there is a high likelihood that the newborn baby will develop very severe bilateral conjunctivitis within 3–5 days of birth, with swollen eyelids and profuse, thick, yellow discharge (Figure 1). The condition can lead to corneal abscesses and blindness.

If the mother has chlamydia, there is a high likelihood that the baby will develop swollen eyelids and discharge within 5–14 days after birth. If untreated, it may cause corneal scarring as well as lung infections.

### What to do

- If you suspect a newborn has one of these conditions, **refer them urgently (on the same day if possible)** to a hospital where there is an ophthalmologist.

- Explain to parents the seriousness of the condition, i.e., the risk to their baby's sight and health. Explain the dangers of traditional treatments and the importance of getting to the hospital without delay (ideally on the same day).
- Wash your hands thoroughly after examining these babies, as gonorrhoea is highly infectious, and it's not possible to be sure which condition is responsible for the discharge you are seeing.

### What care is needed?

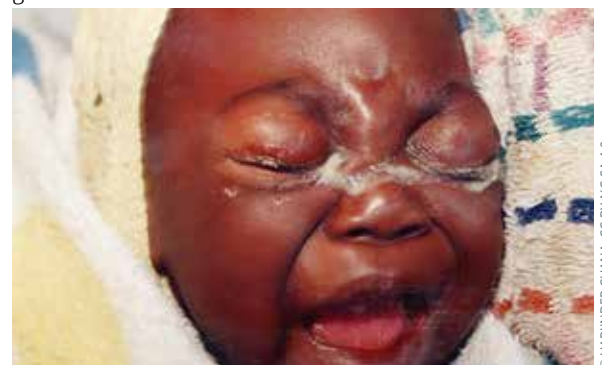At the hospital, investigations will be done to determine which organism is responsible, so the correct antibiotic can be given.

If **gonorrhoea** is confirmed, the recommended treatment is ceftriaxone as a single dose of 25–50 mg/kg intramuscular or intravenous, up to a maximum of 125 mg. Note: penicillin is no longer recommended, as the bacteria responsible has become resistant to penicillin in many countries.

If **chlamydia** is confirmed, the recommended treatment is oral azithromycin 20mg/kg once daily for three days, or oral erythromycin 50 mg/kg/day, divided into 4 doses, for 14 days.

Parents and their sexual partners will require treatment if they have either of these conditions.

**Figure 1** A baby with profuse discharge due to gonococcal infection.



## Newborns and babies with watering eyes

Two very different conditions can cause watering eyes in newborn and young babies whose eyes are **not red**: one is a **blocked tear duct**, which usually resolves after a few months, and the other is **congenital glaucoma**, which can lead to blindness if not managed correctly.

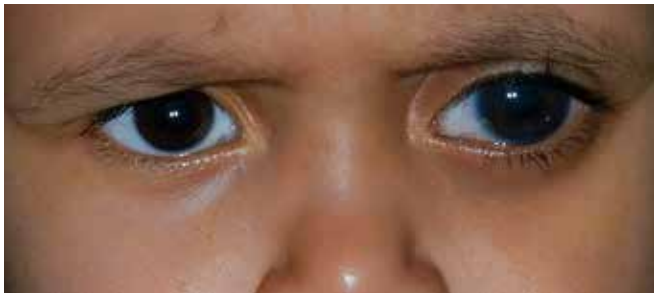If the 'whites' of the eyes are white, the watering eyes are likely due to a **blocked tear duct** when:

- Both eyes are a normal size
- Both corneas are clear and bright
- The baby is not distressed or in pain
- The baby does not object to a bright light.

If the 'whites' of the eyes are white, the watering eyes are likely due to **congenital glaucoma** (Figure 2) when:

- One or both eyes are larger than normal (known as buphthalmos)
- The cornea(s) are hazy or cloudy (although this may not be visible)
- The child objects to a bright light and seems to be in pain.

**Figure 2** This child has congenital glaucoma in the left eye, which is larger than the right eye.



© ABDULRAHMAN HBADAWI CC BY-NC-SA 4.0

### What to do

If you suspect a **blocked tear duct**:

- Reassure the parents that it is likely to get better.
- Suggest that parents try tear duct massage, a common treatment for a blocked tear duct: press a clean fingertip against the inner corner of the eye (nearest the nose) and massage downwards, towards the tip of the nose. Parents can do this several times a day, which may help to clear the blockage.
- Tell parents to bring their child back at the age of 9 months if the eye is still watering.
- If the tear duct is still blocked at 9 months, refer the child for a minor procedure to unblock the duct.

If you suspect **congenital glaucoma**:

- Refer the child **urgently** (within 1 week) to a hospital with an ophthalmologist specialising in child eye care.

**Figure 3** White pupils in both eyes, due to cataract. **INDIA**



© RAJENDRA DAS CC BY-NC-SA 4.0

- Explain to the parents or carers that, the sooner the child is treated, the better the results will be.

### What care is needed

Read the article on congenital glaucoma in this issue for more information on the diagnosis, treatment, and long-term management of this condition.

## A baby or child with something white inside the eye

The parent or carer may say they have noticed "something white" or a "reflection" in one or both eyes of the child. Mothers often notice this while breastfeeding.

Ask the mother whether there is a family history of **childhood cataract** (opacity of the lens) or **retinoblastoma** (a malignant tumour of the retina), as these are the two most important causes of a white reflex (also known as leukocoria) in children.

Another cause of a white reflex, if the baby was born prematurely, is **retinopathy of prematurity (ROP)**, a condition that is preventable but potentially blinding. Premature babies must be examined by an ophthalmologist within the first month of life, as blindness can develop rapidly. Refer the child if needed. Visit [www.cehjournal.org](http://www.cehjournal.org) to read our 2017 issue on this topic.

### What to do

- Examine the eyes to see if they are straight or whether a squint is present (see Figure 5).
- If you have an indirect ophthalmoscope or Arlight, try to elicit the fundal (red) reflex.
- Even if you cannot see anything wrong, it is always advisable to believe what the mother has said.
- **Refer the child urgently to an ophthalmologist**, even if you cannot see anything wrong and there is no family history. Explain to the carers that it is very important that the child is examined by an eye care specialist as soon as possible (in less than 1 week).

### What care is needed

- A child with **cataract** (Figure 3) must undergo surgery to remove the cataract as soon as possible, so that light can reach the retina and the brain can develop normally. If the cataract is removed too late, the child may not be able to see with that eye, as the necessary brain development did not take place. See the article about congenital cataract in this issue.
- A child with **retinoblastoma** (Figure 4) must receive urgent treatment to prevent the cancer from spreading further, which can result in the death of the child. Visit [www.cehjournal.org](http://www.cehjournal.org) to read the *Community Eye Health Journal* issue on retinoblastoma, published in 2018.

**Figure 4** A child with retinoblastoma in the left eye. **INDIA**



© CHALAMALA JANGAIAH CC BY-NC-SA 4.0

## A baby or child with a painful red eye (or eyes)

If a baby or child presents with one or both eyes that are red, painful, and light sensitive, they may have a corneal ulcer. Gently open the eye and examine it using a torch or an Arclight ophthalmoscope. If you can see a cloudy patch on the surface of the cornea, this is likely to be a corneal ulcer. If the ulcers are the result of measles infection and/or vitamin A deficiency, both eyes will be affected.

Corneal ulcers can result in corneal scars and blindness if they are not treated in time.

### What to do

- If you suspect vitamin A deficiency, give the child a high dose of vitamin A (100,000 IU if aged 6–12 months and 200,000 IU if aged 6–59 months).
- Even if you cannot clearly see a corneal ulcer, refer the child **very urgently (ideally within 1 day)** to the nearest hospital where there is an ophthalmologist.
- Explain to parents the seriousness of the condition and the need for their child to be seen without delay.
- Explain the dangers of traditional treatments or remedies.

### What care is needed

- The child needs to undergo urgent investigation to determine the cause of the ulcer so the correct treatment can be given.

## Parents say their child cannot see properly

If a parent or caregiver thinks their child cannot see properly, find out why they think this is so.

- **For children aged up to one year**, ask whether the child smiles back when the mother smiles at them, or whether they follow the mother with their eyes when she moves around in front of them.
- **For children who can walk**, ask if the child bumps into things or falls over objects on the ground, or has become less mobile.

### What to do

- 1 Examine the eyes with a torch to check the cornea for any abnormalities, such as haziness or cloudiness associated with congenital glaucoma or corneal ulcers.
- 2 Perform the red reflex test to check for abnormalities inside the eye, such as cataract or retinoblastoma.
- 3 If you cannot see any abnormalities, the problem may be inside the eye; for example due to refractive error or conditions affecting the optic nerve or retina. Believe the parent(s) and refer the child **urgently (within one week)** to a hospital with an ophthalmologist.

### What care is needed

The child may have a refractive error and need spectacles, or they may have a form of cerebral visual impairment.

## A child whose eyes are not straight

Before the age of 3 months, the eyes do not work together very well, and may – at times – not appear to look in the same direction at the same time (appear 'straight'). After the age of three months, the eyes should appear straight most of the time. This should gradually improve until, by six months of age, children's eyes should appear straight all of the time.

**Figure 5** Child with a squint; the left eye is turning in.

PAKISTAN



© JAMSHYD MASUD CC BY-NC-SA 4.0

### What to do

- Refer **all** children with a squint to an ophthalmologist, as it can be a sign of a serious eye disease, such as retinoblastoma.
- In some communities, a squint is considered attractive, and parents may need more careful counselling. Explain to parents that, if squint is treated too late, the part of the brain responsible for making sense of visual input from that eye will not develop normally, and the child will only be able to see out of their other eye.

### What care is needed

- Children with squint must be examined by an ophthalmologist who can check for, and address, possible causes of squint, such as refractive error, cataract, or retinoblastoma.
- Once these causes are addressed, the squint must be treated. In most children, this is done by patching the 'good' eye for periods of time, so that the brain is forced to use the in-turned eye more.
- Surgery and/or spectacles may be needed to correct a squint.

## Children and adolescents with red eyes (but no pain)

### Conjunctivitis

In the absence of injury, the most common cause of red eyes in children and adolescents is conjunctivitis, which can be due to infection by bacteria or viruses, or it can be caused by allergies.

If conjunctivitis is due to **bacterial or viral infection**, the commonest symptoms are that the eyes feel sore, gritty and watery, and the eyelashes may be stuck together in the morning.

Distinguishing bacterial infection from viral infection can be difficult.

Bacterial infections are more likely when:

- Only one eye is infected
- There is a lot of discharge, and/or the discharge is yellowish and thick/sticky



Viral infections are likely when:

- Both eyes are usually affected.
- There is some discharge (often clear and watery).
- Several children in the family or school have the same symptoms. This is because some of the viruses responsible can be very infectious.

#### What to do

- If it is not clear from the symptoms or history that the child has a viral infection, it is better to err on the side of caution and treat it as a bacterial infection.
- Provide (or prescribe) topical antibiotic eye medication, such as chloramphenicol or gentamicin eye drops, or tetracycline eye ointment.
- Show parents how to instil the drops or apply the ointment.
- Advise parents to do this every 2–3 hours (during the day) to begin with. Depending on the medication and the severity of the child's condition, advise them on how and when to increase the time between treatments, as the infection clears.
- Ask parents to bring the child back in 2–3 days, so you can check whether the infection is resolving.
- Tell parents to visit a hospital immediately if new symptoms such as pain and sensitivity to light develop, as this could suggest their child has a corneal ulcer.
- If the infection does not resolve, refer them to a hospital where there is an ophthalmologist.
- Explain to parents the dangers of using traditional remedies in the eyes.

#### Allergic conjunctivitis

There are two broad types of allergic conjunctivitis – one is **acute** (it comes on quickly and usually resolves), and the other is **chronic** (it can last for several years).

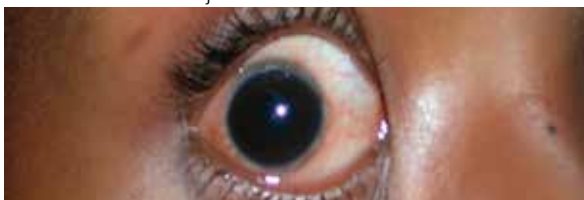In the **acute** form, the eyelids can become very swollen and the eyes become red and very watery. This form of conjunctivitis usually resolves once the person is no longer exposed to whatever caused their allergic reaction (the allergen), but it can sometimes persist.

The **chronic** form of allergic conjunctivitis, also known as **vernal conjunctivitis**, is more common in children with other allergic conditions such as asthma or eczema. The eyelids are slightly puffy, with a stringy discharge. The eyes can become very sensitive to light. In African and Asian children, the white of the eyes can become brownish (Figure 6).

#### What to do

- If a child has **acute allergic conjunctivitis**, offer antihistamine eye drops such as sodium cromoglycate and consider oral antihistamines.
- **Refer** children with **vernal conjunctivitis** to a hospital where there is an ophthalmologist, as they can develop corneal ulcers. Explain to the parents that these children may need long-term treatment and follow-up.

**Figure 6** A child with chronic allergic conjunctivitis, also known as vernal conjunctivitis. **INDIA**



#### Eye injuries

Eye injuries are relatively uncommon in preschool-aged children; they increase as children get older.

#### Blunt or sharp injuries

Injuries can be blunt, caused by objects such as stones or balls, or sharp, caused by objects such as scissors or plant material. Sharp injuries include eye lacerations, such as cuts, tears, or perforations (Figure 7).

#### What to do

- Ask the parent or carer what they saw happen, or what they were told happened.
- To be on the safe side, referral is recommended for all eye injuries, as a detailed eye examination is required to see the extent of the injury.

#### Chemical burns

Some chemicals can burn the eyes, particularly highly alkaline solutions such as bleach (Figure 8).

#### What to do

- If you suspect a chemical entered the eye, first aid is needed. Thoroughly irrigate the eyes using sterile water or saline for at least 20 minutes.
- Refer the child **very urgently (on the same day)** to a hospital with an ophthalmologist.

#### Older children with poor vision

The most common cause of poor vision in children aged 9–10 years and above is short-sightedness (myopia). The parent or caregiver may notice one or more of the following:

- The child holds things too close to their eyes
- They sit near the screen to watch TV
- They narrow their eyelids when trying to see something.

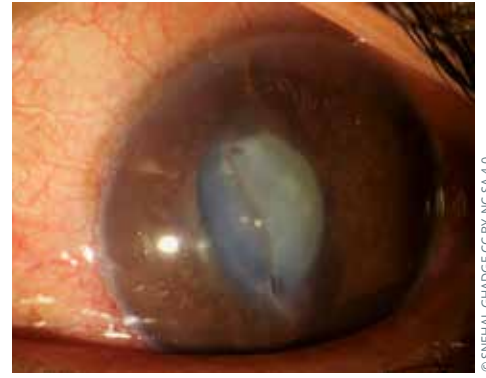#### What to do

Refer these children for a thorough eye examination, including refraction by an ophthalmologist or optometrist, as they may need spectacles.

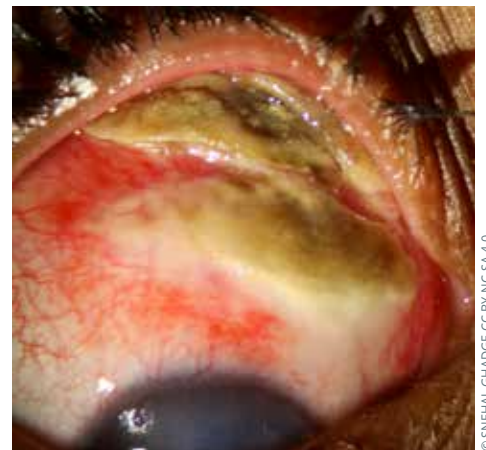In conclusion, many common eye conditions in children can be managed at the primary level by either treatment or referral.

Taking a careful history and examining the eyes should give you an indication of what to do. As some conditions are blinding if not diagnosed and managed promptly, refer the child if you are in any doubt. It is important to explain the condition, and how it is treated, very clearly to the carers, and to explain why the referral is urgent, if applicable.

**Figure 7** Corneal laceration due to a sharp object, resulting in damage to the lens. **INDIA**



**Figure 8** Acute alkali burn. **INDIA**



**“Many common eye conditions in children can be managed at the primary level by either treatment or referral.”**



**P Vijayalakshmi**  
Senior Paediatric Ophthalmologist and Chief of Vision Rehabilitation Center: Aravind Eye Care System, Madurai, India.

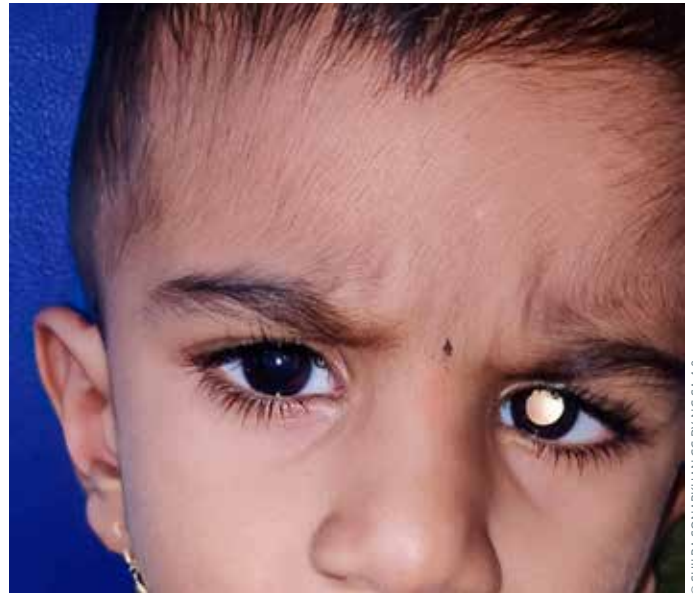# Detecting vision problems in children

Screening can detect eye conditions early – which is especially important in children, who need good vision in order to develop.

The purpose of screening the eyes of children is to detect specific conditions in as many children in the population as possible, as soon as possible. The types of eye conditions that benefit from screening are those for which early detection and treatment improves visual or health outcomes, and for which there are reliable screening tests that are simple to use, and safe.

Screening on its own is not enough, however. There must also be eye care services where the children who fail screening tests can undergo a comprehensive eye examination to diagnose why they failed the test, and where they can receive effective treatment.

The eye conditions in children that can usefully be screened for are summarised in Table 1. The screening tests listed in Table 1 may also detect conditions which are not treatable. However, **all**



A child with retinoblastoma in the left eye, visible when using a torch light or ophthalmoscope to elicit the red reflex. INDIA

children who fail **any** screening test must be referred for examination by an eye care professional. For example, torchlight examination of a newborn may detect microphthalmos, and fundal (red) reflex testing may detect choroidal coloboma. Neither of these conditions need immediate intervention, but it is important to make the diagnosis.

## Newborn screening

Screening the eyes is now recommended by the World Health Organization as part of the general examination of all newborns.<sup>1</sup> This can be done by the same person who carries out the general newborn examination, once they have received some additional training.

There are two parts to newborn eye screening:

- 1 Using a torch to look at the eyelids, to check the size of the eyes and the clarity of the corneas.
- 2 Eliciting the fundal (red) reflex, which can be done with a direct ophthalmoscope such as the Arclight. Sometimes, the eyelids of newborns are a bit swollen and red reflex testing is difficult; the test can then be delayed until the baby is 6–8 weeks old.

Arclights can easily be attached to a smartphone, which means you can take a video or photographs (Figure 1b). This is useful if you want to discuss what you have seen with somebody else.

Arclights have a small solar panel and batteries are not necessary; they are very light and inexpensive (US \$10–15) and come with a lanyard and an otoscope for examining ears. Fundal reflex testing can also be undertaken in young children (and people of any age).

Teaching videos can be found here <https://tinyurl.com/CEHJarclight>

Screening **preterm babies** for retinopathy of prematurity is covered in detail in an earlier issue of the Journal (<http://tinyurl.com/CEHJretinopathy>).

**Table 1** Eye conditions which can be screened for in children and adolescents in different age groups

Age	Conditions to screen for	Screening tests and tools	Who can screen
<b>Preterm neonates</b>	<ul style="list-style-type: none"> <li>Retinopathy of prematurity (ROP)</li> </ul>	<ul style="list-style-type: none"> <li>Retinal examination (using an indirect ophthalmoscope)</li> <li>Retinal imaging with remote image grading</li> </ul>	<ul style="list-style-type: none"> <li>Ophthalmologist (clinical examination using an indirect ophthalmoscope)</li> <li>Technician or nurse (retinal imaging) followed by grading by an ophthalmologist</li> </ul>
<b>Newborns up to 5 years</b>	<ul style="list-style-type: none"> <li>Structural abnormalities of the eyelid</li> <li>Eye size</li> <li>Corneal clarity</li> <li>Squint</li> </ul>	<ul style="list-style-type: none"> <li>Torchlight examination</li> </ul>	<ul style="list-style-type: none"> <li>Trained primary health care worker</li> <li>Pediatrician</li> <li>Experienced health professional</li> </ul>
	<ul style="list-style-type: none"> <li>Lens opacities (cataract)</li> <li>Retinoblastoma</li> </ul>	<ul style="list-style-type: none"> <li>Red reflex test (using an indirect ophthalmoscope or Arclight)</li> </ul>	<ul style="list-style-type: none"> <li>Trained primary health care worker</li> <li>Pediatrician</li> <li>Experienced (eye) health professional</li> </ul>
<b>Children aged 6 years and above (including adolescents)</b>	<ul style="list-style-type: none"> <li>Vision impairment</li> <li>Amblyopia and squint</li> </ul>	<ul style="list-style-type: none"> <li>Visual acuity test</li> <li>Torchlight examination</li> </ul>	<ul style="list-style-type: none"> <li>Teachers</li> <li>Health professionals</li> </ul>



## Preschool-age screening

The same screening tests as for newborns can be used for preschool-aged children.

Whether preschool children should also be screened for amblyopia ('lazy eyes') is controversial, as this would require measuring their visual acuity, which can be very difficult.

A torchlight examination and fundal reflex testing should detect squint – a common cause of amblyopia. There is also very limited evidence on whether the management of amblyopia due to uncorrected refractive error (such as intermittent patching of the 'good' eye before the age of 5 years) has better outcomes than management after the age of 5 years.<sup>2</sup>

Screening preschool-aged children for refractive errors is also controversial, as they are too young to have developed myopia (short sightedness). Hyperopia (longsightedness), if present, resolves spontaneously in most young children.

## Children aged 6 years and above (including adolescents)

The main purpose of screening school-age children is to detect and manage **uncorrected refractive errors**. The most common screening test is a visual acuity measurement during which only one line of the Snellen chart needs to be used – either the 6/9 line or the 6/12 line. Each eye is tested separately.

All children who fail the screening test should undergo refraction by an experienced optometrist, who then also measures the corrected visual acuity. If the vision does not improve, the child needs to be examined to rule out other causes of vision impairment.

If correction does improve the vision, it is important to follow the prescribing guidelines drawn up by IAPB (<https://tinyurl.com/ypnja65y>). Children whose vision only improves by one line of acuity are very unlikely to wear their spectacles, for example.<sup>3</sup>

Autorefractors and other technology can aid the screening process, but more evidence is needed on their effectiveness.

The age at which vision screening should start is very context-specific and depends on the age at which myopia commonly starts to develop in the child population in that country or region. For example, in China and southeast Asian countries, myopia can start at primary school age, and screening younger children is, therefore, warranted. However, in other parts of the world, myopia doesn't usually start until the age of 9 to 11 years.

School eye health programmes should not focus solely on detecting uncorrected refractive errors, as some children will have other conditions which need treatment, such as infective or allergic conjunctivitis, squint, or cataract.

## Summary

Screening, using the range of methods outlined above, can detect eye conditions early. For all age groups of children, it is very important that processes are put in place to ensure that children who fail a screening test are examined by an eye health professional for a diagnosis, and that treatment is provided as soon as possible, whether it is spectacles, cataract surgery, or treatment of retinoblastoma or amblyopia.

## References

- 1 WHO recommendations on maternal and newborn care for a positive postnatal experience. Geneva: World Health Organization; 2022. Licence: CC BY-NC-SA 3.0 IGO
- 2 Ameenat Lola Solebo, Phillippa M Cumberland, Jugnoo S Rahi. Whole-population vision screening in children aged 4–5 years to detect amblyopia. *Lancet* 2015; 385: 2308–19
- 3 IAPB School Eye Health Work Group 2018. Standard school eye health guidelines for low and middle-income countries <https://tinyurl.com/cvxejtrj>

## How to elicit the fundal (red) reflex using the Arclight ophthalmoscope

Figure 1a The Arclight ophthalmoscope



Figure 1b Arclight attached to a smartphone



- 1 Set the lens of the Arclight or direct ophthalmoscope to 0.
- 2 Explain to the mother what you are going to do.
- 3 Position yourself so that you are about a metre away from the baby or child, with your eyes at the same level as the baby's eyes.
- 4 If the baby's eyes stay closed, ask the carer to hold the baby over their shoulder; this usually makes the baby lift up their head and open their eyes.
- 5 Shine the Arclight into the baby's eyes so that you can see the reflex in both eyes at the same time. This enables you to compare them.
- 6 Look carefully at the reflex in both eyes to see whether the reflexes are the same colour and brightness in both eyes. Is there a 'shadow' obscuring part or all of the reflex?

Figure 2 Normal fundal reflex in Caucasian children (a and b). In African and Asian babies, the normal reflex can have a blueish appearance (c).

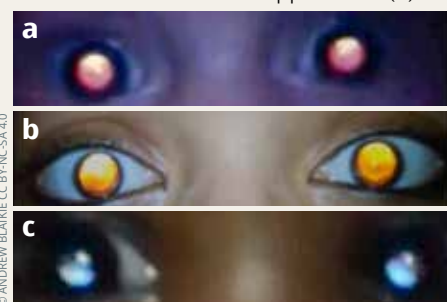
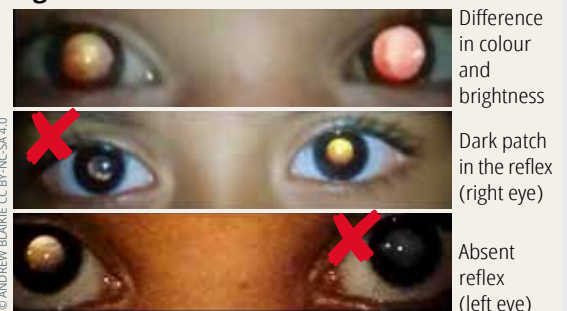
Figure 3 Abnormal fundal reflexes





**Vera Adobe Essuman**  
Professor of Paediatric Ophthalmology: University of Ghana Medical School, Accra, Ghana.



**Vera Mawusime Beyuo**  
Paediatric Ophthalmologist: Lions International Eye Centre, Korle Bu Teaching Hospital, Accra, Ghana.

# Congenital glaucoma: the ‘not-so-silent’ thief of sight in children

Congenital glaucoma is an important cause of blindness in very young children, but vision can be preserved if it is identified and treated as early as possible.

Although uncommon, congenital glaucoma is an important cause of blindness in children, particularly in low-resource settings, where children are often only seen once the disease has progressed and parents find it difficult to attend regular, long-term follow-up visits. Early detection and treatment, which is usually surgical in the first instance, can preserve vision.

## What is congenital glaucoma?

Congenital glaucoma, which is usually bilateral, can be present at birth or become apparent during the first few years of life. In congenital glaucoma, high intraocular pressure (IOP) causes the eye(s) to enlarge (unlike in adults or older children where the size of the eye does not change). This enlargement of the eye is known as buphthalmos, or ‘ox eye’ (Figures 1).

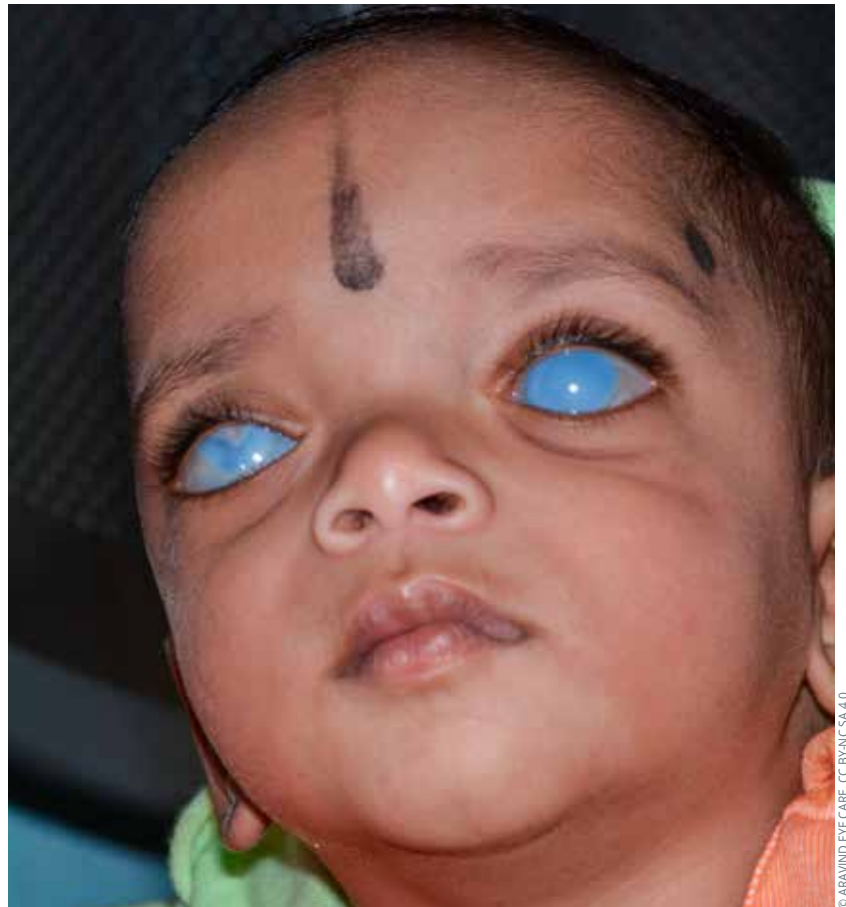Congenital glaucoma causes progressive damage to the optic nerves and cornea, as well as thinning of the sclera. The incidence varies with ethnicity, ranging from 1 in 2,500–8,200 live births in the Middle East to 1 in 10–20,000 live births in Western populations.<sup>1,2</sup> Worldwide, congenital glaucoma is responsible for 5–18% of blindness in children.<sup>3</sup>

## Definitions and causes

Congenital glaucoma can be primary or secondary, according to the 9th World Glaucoma Association Consensus.<sup>4</sup>

### Primary congenital glaucoma

This is caused by genetic mutations, leading to abnormal development of the trabecular meshwork, resulting in obstruction to aqueous outflow and high IOP. The genes involved include CYP1B1 and LTBP2.<sup>4</sup> Consanguinity (marriage between close relatives such as cousins) increases the risk.



**Figure 1** A child who presented late with congenital glaucoma in the left eye. The whole eye, including the cornea, is enlarged (buphthalmos) and the cornea is hazy.

In some children, the condition may be apparent from birth. In other children, the eyes may appear normal at birth and the condition only becomes apparent later. Subcategories of primary congenital glaucoma are therefore based on the age of onset:

- Neonatal onset (birth to 1 month)
- Infantile onset (>1 month to 24 months)
- Late onset or late recognised (>2 years).

If children have the typical signs of primary congenital glaucoma, but these do not progress, and they have normal IOP and optic discs, their condition is classified as spontaneously arrested congenital glaucoma.

### Secondary congenital glaucoma

Secondary congenital glaucoma is associated with a variety of ocular and systemic syndromes, mainly:

- Other congenital eye anomalies, such as Peter’s anomaly or aniridia, which may or may not be associated with systemic anomalies
- Systemic diseases or syndromes, such as Sturge-Weber syndrome, neurofibromatosis, and congenital rubella syndrome, which may be associated with eye signs, including signs of congenital glaucoma.

It is important to distinguish between primary and secondary congenital glaucoma. In secondary congenital glaucoma, the IOP can be harder to control, and the outcomes of management can be worse. Affected children also need to be referred to a paediatrician to manage any systemic abnormalities, such as heart defects associated with congenital rubella syndrome.

### What to look for at the local/primary level and when to refer

Mothers typically say that they have noticed three things wrong with their child's eyes:

- 1 Excessive watering (epiphoria)
- 2 Avoidance of bright light (photophobia)
- 3 Excessive blinking (blepharospasm).<sup>4</sup>

They may also notice that the corneas look hazy.

Signs to look for include:

- Enlargement of the eye(s), known as buphthalmos
- Enlargement of the cornea
- Corneal haziness due to oedema.

The child may also show signs of distress due to pain.

In most low-resource settings, children present late, with signs of advanced disease with marked corneal haziness or opacity. **Any children in whom glaucoma is suspected should be referred urgently to an eye department or hospital where there is a paediatric ophthalmologist.**

### Diagnosis at the tertiary level

At the tertiary (or teaching hospital) level, it is important to make the diagnosis and identify whether the child has primary congenital glaucoma or secondary congenital glaucoma. This is because the management can be different, and the prognosis is usually better for primary congenital glaucoma. A multidisciplinary team is needed, including anaesthetists, paediatricians, orthoptists, optometrists, counsellors, and possibly social workers.

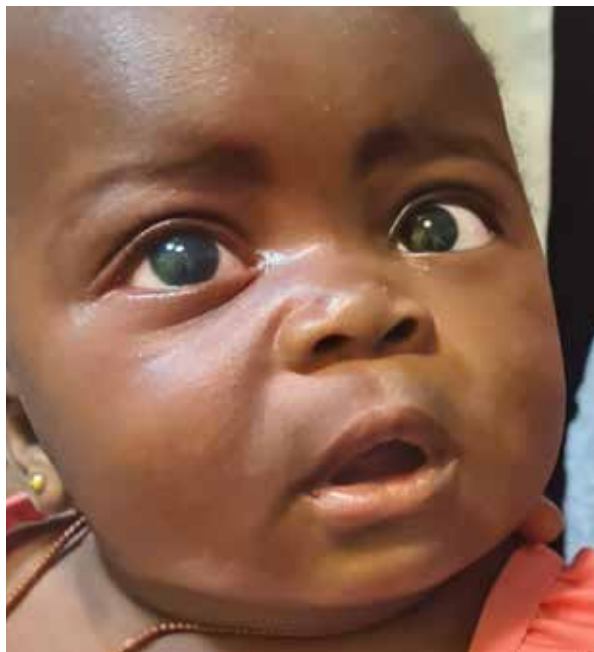The diagnosis is made clinically.

- Ask the parents or carers about other problems which may help to distinguish between primary or secondary congenital glaucoma. For example, whether the parents are close relatives (suggestive of primary glaucoma), whether the baby had a rash at birth (suggestive of congenital rubella, a cause of secondary glaucoma), or whether the parents have noticed any other problems from birth (also suggestive of secondary glaucoma).
- Examination should include a systemic examination, looking for signs which suggest that the child may have secondary congenital glaucoma.
- Measure the visual acuity, if possible, and examine the anterior and posterior segments of the eyes.
- Sedation or anaesthesia is helpful to enable a thorough examination. Oral chloral hydrate, 50–80 mg/kg, can be used for sedation, with the advantage that it does not lower the IOP very much.
- The anterior segment can be examined with a hand-held slit lamp or torch and a 15D or 20D lens. Look for splits in Descemet's membrane in the cornea

(Haab's striae), which indicate that the cornea has enlarged as a result of high IOP. Note any thinning of the sclera and whether a staphyloma is present.

- To assess whether the eye or eyes are larger than normal, measure the horizontal corneal diameter, from 'white to white' limbus, using callipers. The cornea is enlarged if it is wider than the values below:
  - >11 mm in a newborn
  - >12 mm in infant aged 1 to 12 months
  - >13 mm (any age)
- Note any corneal haze. Grade this if possible, as grading helps with follow-up assessment and may be important for medicolegal reasons.
- Measure IOP using a Perkins tonometer, a Tonopen, or an iCare device.
- Posterior segment examination is possible if the cornea is clear enough to visualise the optic disc. In case there is poor visualisation due to corneal oedema, the view of the posterior segment can be improved by gently removing the corneal epithelium if the child is being examined under general anaesthesia, prior to gonioscopy. In congenital glaucoma, optic disc cupping tends to be circumferential initially, as it appears the cupping is due to stretching of the sclera posteriorly. However, there may be areas of focal thinning and atrophy as the disease progresses.
- The Congenital Glaucoma Research Network (CGRN)<sup>4</sup> recommends that gonioscopy should be done at least once. This helps to identify changes, sometimes very subtle, that are suggestive of a secondary cause.

**“Any children in whom glaucoma is suspected should be referred urgently to an eye department or hospital where there is a paediatric ophthalmologist.”**



© VERA MAWUSIME BEYUO CC BY-NC-SA 4.0

A child with secondary congenital glaucoma in the right eye associated with Sturge-Weber syndrome. Note the following: right hemifacial hypertrophy, port-wine birthmark (difficult to see in dark-skinned children), conjunctival injection, and buphthalmos with an enlarged, hazy cornea.



## Other investigations at tertiary level

The following investigations are useful to support the diagnosis and to monitor the effectiveness of treatment.

**Refraction.** Hyperopia that is below the expected range for their age, or myopia in an infant in the presence of other signs, can confirm the diagnosis of congenital glaucoma. A change in the refractive error over time, particularly if the refraction becomes more myopic, implies that the eyes are getting longer as a result of inadequate IOP control.

### Ultrasound to determine axial length.

Axial length measurement using an A-scan is also useful in confirming the diagnosis and monitoring progression. Normal axial length increases from 16.2 mm at term (37 weeks' gestation) to an average of 21.8 mm at age 3. The rate of growth slows down from 0.62 mm/month (birth to 6 months) to 0.19 mm/month (6–18 months of age), finally slowing to 0.1 mm/month from the age of 18 months onwards.<sup>5</sup>

B-scan ultrasound may reveal intraocular pathology, such as retinoblastoma, responsible for secondary glaucoma. In patients where the discs cannot be visualised due to corneal haze, it can also show whether optic disc cupping is present.

Refraction and axial length measurements can serve as proxies for IOP, as the latter may be difficult to measure at each follow-up visit, particularly in low-resource settings. It is therefore important to gather baseline values by measuring visual acuity and performing an A-scan at the first visit.

## Management at the tertiary level

Angle surgery is the treatment of choice for congenital glaucoma. This includes goniotomy (ab interno approach) or trabeculotomy using ab externo approach (superior, inferior or 360°). Trabeculectomy

is usually undertaken if goniotomy fails. In centres where children often present late, combined trabeculotomy and trabeculectomy is the treatment of choice to optimise outcomes. Topical antiglaucoma medications can also be used as a temporary measure before surgery or when additional treatment is needed to control the IOP after surgery. Trabeculectomy can be very challenging in eyes with buphthalmos, as the sclera can be very thin and the anatomy distorted. Only ophthalmologists who have been trained and have experience should perform these operations.

### Follow-up and long-term management

After surgery, the frequency of follow-up is determined by the findings. Repeat examination under anaesthesia or sedation may be needed to monitor IOP, corneal clarity and diameter, axial length, and refraction. It is important to fully correct any refractive error to prevent amblyopia which may lead to poor visual outcomes, even if the IOP is controlled and the corneas have cleared. If amblyopia is suspected, start occlusion therapy as soon as possible.

Counselling parents or caregivers is of vital importance so that they understand the need for regular follow-up, compliance with topical medication if applicable, and that follow-up needs to be lifelong. When the children are older, they should also be counselled.

### Prognosis and complications

Vision can be preserved with good IOP control as this prevents disease progression and helps protect the optic nerve. Young children with primary glaucoma who present early have the best prognosis. Loss of vision from congenital glaucoma can be due to optic nerve damage, amblyopia, high myopia and its complications, astigmatism, and/or lens dislocation.

**“Counselling parents or caregivers is of vital importance so that they understand the need for regular follow-up.”**

## References

- 1 Elder MJ. Congenital glaucoma in the West Bank and Gaza Strip. *Br J Ophthalmol.* 1993;77(7):413-6.
- 2 Papadopoulos M, Cable N, Rahi J, Khaw PT, BIG Eye Study Investigators. The British Infantile and Childhood Glaucoma (BIG) Eye Study. *Invest Ophthalmol Vis Sci.* 2007;48(9):4100-6.
- 3 Rahi JS, Gilbert CE. Epidemiology and the world-wide impact of visual impairment in children. In: Hoyt C, Taylor D, eds. *Pediatric Ophthalmology and Strabismus.* 6th ed. London: Elsevier, 2021.
- 4 RN Weinreb, AL Grajewski, M Papadopoulos, J Grigg and S Freedman, eds. *WGA Consensus Series 9: Childhood Glaucoma.* Amsterdam: Kugler Publications, 2013. <https://wga.one/consensus-9>.
- 5 Groot ALW, Lissenberg-Witte BI, van Rijn LJ, Hartong DT. Meta-analysis of ocular axial length in newborns and infants up to 3 years of age. *Surv Ophthalmol.* 2022;67(2):342-352.



**Rilwan Muhammad**

Consultant  
Ophthalmologist,  
University of Abuja  
Teaching Hospital,  
Gwagwalada, Abuja,  
Nigeria.

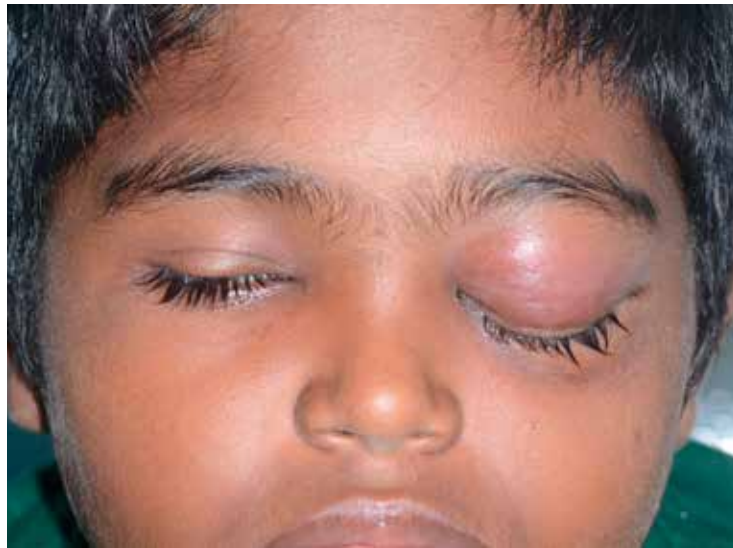

**Fatima Kyari**

Consultant  
Ophthalmologist,  
University of Abuja  
Teaching Hospital,  
Gwagwalada, Abuja,  
Nigeria.

# Preseptal and orbital cellulitis: how to identify and treat these conditions – and save lives

Preseptal and orbital cellulitis can be difficult to distinguish clinically. It is important to know what to look for so you can identify which children are at risk of serious complications, as they may need support from a multidisciplinary team.



A child with orbital cellulitis who was admitted for treatment. INDIA

There are two main types of cellulitis that affect the tissues around the eye. Both are usually unilateral, affecting just one eye.

**Preseptal (sometimes known as periorbital) cellulitis** is an infection of the soft tissues around the eye **in front** of the orbital septum, the thin sheet of connective tissue which extends from the bony rim of the eye socket to the tarsal plates in the eyelids (Figure 1).<sup>1,2</sup>

**Orbital cellulitis** is an infection of the soft tissues **behind** the septum, inside the orbital cavity. Orbital cellulitis is a serious and potentially life-threatening condition which requires an early diagnosis and prompt treatment with antibiotics, as the infection can spread into the brain.<sup>1,2</sup>

Some children can have features of both preseptal and orbital cellulitis.

## Causes of preseptal and orbital cellulitis

There is considerable overlap between the causes of preseptal and orbital cellulitis and the history alone cannot always distinguish the two. A computed tomography (CT) or magnetic resonance imaging (MRI) scan may be needed.<sup>1,2</sup>

**Preseptal cellulitis** can be caused by an insect bite, by an injury to the skin around the eye, or by spread of infection from a styne or an infected cyst in the eyelid. If there is no obvious eyelid cause, the infection may have spread from the sinuses – the bony spaces within the bones around the orbit (Figure 1).

**Orbital cellulitis** is more common and more severe in children and adolescents than in adults. In most cases (90%) the infection spreads into the orbit from the sinuses next to the nose (see Figure 1). Infection can also spread from eyelid skin, the lacrimal sac, or the teeth and gums, and may follow penetrating injuries of the orbit or surgery around the eye. Infection can also spread, via the bloodstream, from the upper respiratory tract and ears. In children, preseptal cellulitis can also, occasionally, progress to orbital cellulitis.

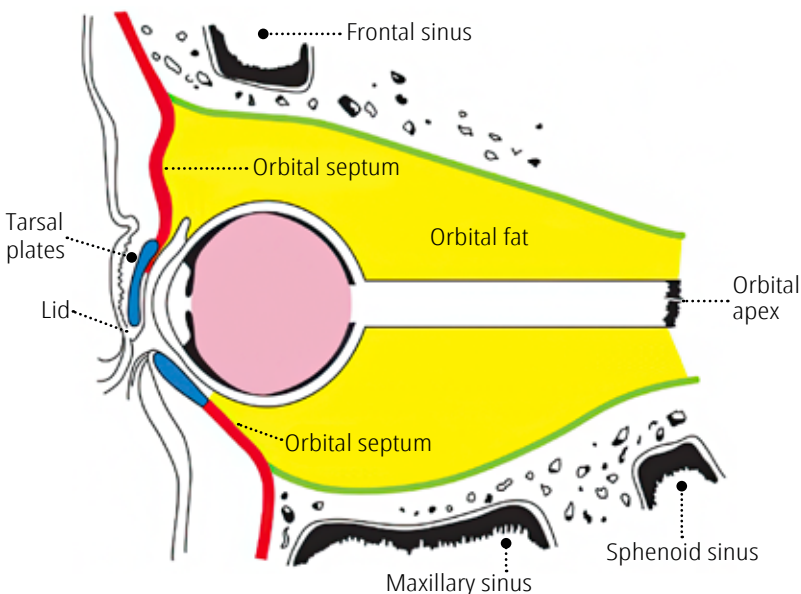
The most common bacteria responsible for orbital cellulitis are Gram-positive cocci: *Staphylococcus aureus*, *Streptococcus* species (*S. pyogenes* and *S. pneumoniae*) and *Haemophilus influenzae*. Gram-negative bacilli may cause the infection in neonates, and following trauma.

## What to look for and ask about at the local or community level, and when to refer

Because the consequences of missing orbital cellulitis can be life-threatening, we recommend **urgent** referral of children where either orbital or preseptal cellulitis are suspected.

You should think of preseptal or orbital cellulitis, and not another cause of a swollen eyelid, if you see a child with any of the following:

**Figure 1** The septum (shown in red) is a sheet of thin connective tissue which extends from the bony prominence around the eye and attaches to the eyelids. It stops the orbital fat (the yellow area) around the back of the eye from coming forward into the eyelids.



- Red, swollen eyelids affecting either the right or the left eye
- Eye pain, or tenderness of one eye
- Drooping of the eyelid (ptosis)
- History of insect bite, lid trauma, or an upper respiratory tract, dental, or ear infection.

Ask the carer if the child has had an insect bite or trauma to the eyelid or whether they have, or have recently had, an upper respiratory tract infection, earache, or toothache.

If the eyelids are swollen in both eyes, and the eyes are watering and itchy, consider allergic conjunctivitis. In allergic conjunctivitis, the surrounding skin is usually a normal colour, whereas in an infective cause such as cellulitis, the surrounding skin is red.

If a newborn baby has these signs in both eyes, with thick discharge, they are likely to have conjunctivitis of the newborn due to chlamydia or gonococcal infection. Urgent referral is needed.

### Diagnosis and management in the eye department

The first thing to do is decide whether the child has preseptal or orbital cellulitis and not another condition causing marked lid swelling on one side. Other causes of swelling around the eye with proptosis in children include a retinoblastoma which has extended into the orbit, or a rhabdomyosarcoma.

The next step is to decide whether the child has preseptal cellulitis or orbital cellulitis, as the management is different.

It can be difficult to decide whether a child has preseptal or orbital cellulitis. Table 1 summarises the different features. In orbital cellulitis, reduced vision and pupil abnormalities suggest that the optic nerve is involved, and that there is optic nerve compression.

An orbital CT or MRI scan may be needed to exclude non-infectious causes of the lid swelling and proptosis, such as retinoblastoma or rhabdomyosarcoma, and to distinguish preseptal from orbital cellulitis. It is important to bear in mind that B scans cannot reliably differentiate between an orbital abscess and a tumour.

#### Management of preseptal cellulitis

If the child has **preseptal cellulitis**, start treatment with oral broad-spectrum antibiotics such as flucloxacillin and co-amoxiclav. Follow local guidelines for soft tissue infection and adjust the dose according to the age and weight of the child. The child should be closely followed up.

**Table 1** Features of preseptal and orbital cellulitis.<sup>3</sup>

Feature	Preseptal cellulitis	Orbital cellulitis
History	Insect bite or trauma around the eye	Upper respiratory tract infection, toothache, earache, headache
Protruding eye (proptosis)	Absent	Present
Eye movement	Normal	Painful, restricted
Visual acuity	Normal	Reduced in severe cases
Colour vision	Normal	Reduced in severe cases
Pupil abnormality (relative afferent pupil defect, RAPD)	Normal	Present in severe cases

#### Management of orbital cellulitis

Children with orbital cellulitis should be admitted to hospital, as the management of orbital cellulitis requires a multidisciplinary approach, including paediatricians, ophthalmologists, and ENT surgeons.<sup>1,2,4</sup> Investigations can include CT imaging of the brain and orbit, as well as full blood count, blood culture, and eye, nasal, and throat swabs.

Initial management may involve intravenous antibiotics such as flucloxacillin or ceftriaxone.

The child should be monitored closely in the hospital for signs of disease progression and the development of complications such as orbital and intracranial abscesses, meningitis, and cavernous sinus thrombosis.

The clinical signs and symptoms usually start to improve within 24 to 48 hours of intravenous antibiotics. Further investigations may be required if the clinical signs are not resolving, and/or to detect an underlying cause. These may include a CT scan of the brain, orbit, and paranasal sinuses to rule out subperiosteal and orbital abscesses and intracranial extension (subdural or brain abscesses and meningitis), and to monitor disease resolution or progression.

Further management might be required, such as surgical drainage of an orbital abscess with microbiological culture of fluid, particularly if there are signs of optic nerve involvement, such as reduced vision and abnormal pupil reflexes in the presence of proptosis).

Once the danger signs have resolved, the child can be discharged on oral antibiotics for 1–3 weeks. Explain to parents the importance of completing the course of antibiotics, what symptoms and signs to look out for, and what to do if that happens.

#### Prevention & parent education

The risk of orbital cellulitis can be reduced by the prompt treatment of infections of the upper respiratory tract, sinuses, ears, mouth, and periorcular skin.

#### References

- 1 Stephanie J. Wong and Jessica Levi. Management of pediatric orbital cellulitis: A systematic review. *Int J Ped Otorhinol.* 2018;110:123-129.
- 2 Caldeira Santos, Sara Pinto, Sofia Ferreira, Catarina Maia, Sandra Alves, Vinhas da Silva. Pediatric preseptal and orbital cellulitis: A 10-year experience. *Int J Ped Otorhinol.* 2019;120: 82-88.
- 3 Denniston, AKO and Murray PI (eds), *Oxford Handbook of Ophthalmology*, 4th edition, Oxford Medical Handbooks, Oxford, 2018.
- 4 Anosike BI, Ganapathy V, Nakamura MM. Epidemiology and Management of Orbital Cellulitis in Children. *J Pediatric Infect Dis Soc.* 2022;11(5):214-220.





**Sarah Sitati**  
 Consultant  
 Ophthalmologist,  
 Paediatric  
 Ophthalmology &  
 Strabismus, Kenyatta  
 National Hospital,  
 Kenya. Chair, ROP  
 Working Group  
 Kenya.

# Recognising and managing bilateral cataracts in children

Children may be born with cataracts in both eyes (congenital cataract) or the cataracts may become apparent during the first few years of life. These children need high quality cataract surgery as soon as possible, with good follow-up.

In many low- and middle-income countries, where it often takes a long time before children receive the surgery they need, children who are born with bilateral cataract may remain severely visually impaired after the cataracts have been surgically removed. This is because, in children, dense cataracts need to be operated on as soon as possible, otherwise the part of the brain responsible for visual processing will not develop normally. If cataract surgery happens too late, vision will be blurred or greatly reduced – known as amblyopia, or 'lazy eye'.

Even in children in high-income settings, where bilateral congenital cataracts are detected early and surgery is performed promptly (before 3 months of age), the average corrected visual acuity after surgery is 6/12 (logMAR 0.34).<sup>1</sup> Surgery performed later than 3 months of age will have even poorer outcomes.

Counselling of parents is extremely important at all stages of the child's management, so that they understand why surgery is needed, what will be involved, and what they should expect after surgery. They also need to understand that surgery in children is unlike cataract surgery in adults, which they may have some experience of, and that long term follow-up is of vital importance.

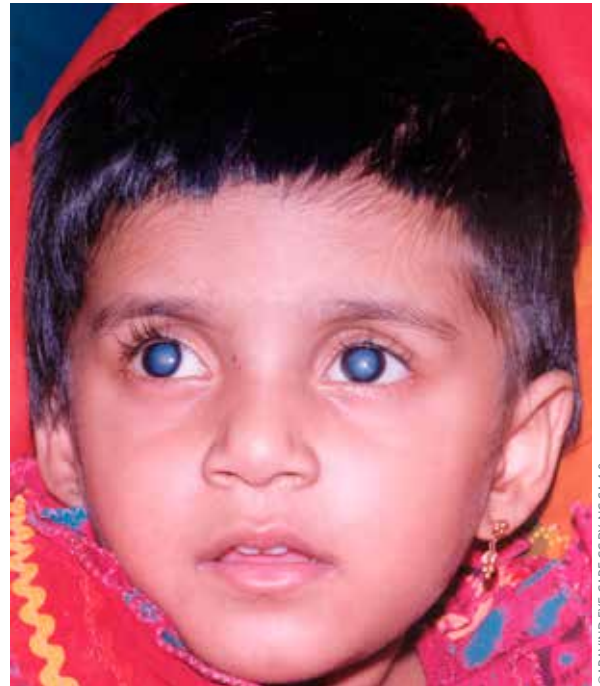## Causes

Bilateral congenital cataracts are often due to genetic abnormalities,<sup>2</sup> but the family history is only positive in approximately 20% of cases. Infective causes, which are unusual in most countries, include congenital rubella syndrome and congenital cytomegalovirus infection. Children with these congenital infections may also have systemic problems, such as heart defects, which have implications for general anaesthesia. Bilateral cataracts may also be associated with other eye anomalies, such as microphthalmos.

Acquired causes of bilateral cataract include topical or systemic steroid use, chronic uveitis, certain drugs, and occasionally trauma. Cataracts in older children can be associated with systemic conditions such as diabetes, or atopic conditions such as eczema.

## What to ask about and look for at community or primary level

Babies may present because the mother has noticed something white in the eyes of her child, or an older sibling may have cataracts.



A child with dense, bilateral cataract. Both eyes are likely to be amblyopic if the cataracts were present since birth. INDIA

In children aged two and above, the carers may notice abnormal visual behaviour: for example, the child does not reach out for or pick up objects, or bumps into (or falls) over things. The carer may also notice that the child has 'wobbly eyes' (nystagmus). Older children may have difficulty reading or problems identifying faces and objects. An abnormal red (or fundal) reflex – which may be noted in photographs – can be noticed at any age.

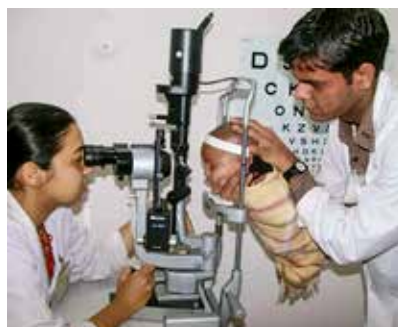Cataracts can be detected in clinics in the community (at primary level) by testing the child's fundal reflex. For more information, see the article on screening in this issue.

## Examination in the hospital eye department

It is important to take a **history** of when the signs were first noticed and ask about a family history of cataract in childhood, past medical history, and systemic history, including whether steroids have been used.

Look to see whether **nystagmus** is present. If so, this means that the child's vision has been very poor from a very young age and their chances of having good visual acuity after surgery are not very good. However, even if their visual acuity is low, the child will have a better field of vision after surgery; this will increase their independence.

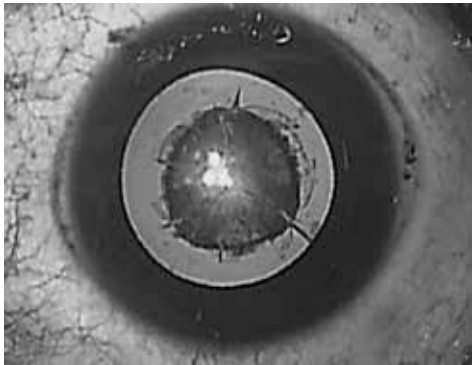
Cataracts can sometimes complicate **retinal conditions** such as total retinal detachment or retinal dystrophies, which means that



Examining a baby at the slit lamp. INDIA

surgery will not benefit the child. Examine the pupil reactions and test light projection. B-scan ultrasound can also be useful.

**Figure 1** Dense central cataract of more than 4 mm in diameter.



Examine the eyes for **signs which would make surgery more difficult (Figure 1)**, such as microphthalmos (small eyes), a central corneal opacity, iris coloboma (“cat’s eye”), or signs of chronic inflammation (bound down, irregular pupils).

Examine the lens through an undilated pupil to assess the location and density of the lens opacities. Estimate the diameter of the opacity

(Figure 1). If the peripheral part of the lens is clear (as in nuclear and posterior subcapsular cataract), try to examine the retina and optic nerve around the opacity using an indirect ophthalmoscope. Retinoscopy can also give useful information about the visual axis.

It is important to assess visual function, as the level of vision is a major factor when deciding whether surgery should be performed straight away or whether it can be postponed. Measuring visual acuity is very difficult in young children, and the vision milestones outlined in Figure 2 could be useful. You can also use a brightly coloured object to check the child’s fixation and following.

**Systemic examination**

The purpose of the systemic examination is to identify clinical signs which may suggest an underlying cause, and to assess whether the child is fit for anaesthesia. If there are concerns that a systemic condition is present, such as developmental delay, microcephaly, cardiac deficits, or hearing anomalies, examination by a paediatrician is indicated to assess fitness for anaesthesia. Echocardiography should be undertaken, if available, when congenital rubella syndrome is suspected. Laboratory tests may be needed, or genetic testing. It is important to note that congenital rubella syndrome can only be confirmed by raised rubella-specific IgM (not IgG) during the first year of life. After that, raised antibodies may be due to acquired rubella.

**Decision making**

After examining the child, is it important to decide:

- 1 Whether surgery needs to be performed straight away
- 2 Whether the child is fit for general anaesthesia.

It is important to bear in mind that cataract surgery and general or ketamine anaesthesia in young children are not without risks, optical correction after cataract extraction can be challenging, and regular follow-up is essential.

Comprehensive examination of children in the clinic may be difficult. However, because of the risks involved, examination under anaesthesia should be avoided unless done on the day of surgery.

**Is surgery needed immediately?**

Findings which mean that surgery should be performed straight away (as long the child is fit for anaesthesia), or could be postponed, are shown in Table 1.

**Table 1** Can congenital cataract surgery be postponed? Findings to guide decision making.

Immediate surgery	Surgery can be postponed
Significant vision impairment or the child has not reached their visual milestones	Visual milestones for their age have been met
Nystagmus is present	No nystagmus
The cataracts are total, or affect 3–4 mm or more of the central part of the lens	The cataracts measure less than 3–4 mm
No, or a very poor, view of the retina	The view of the retina is good or reasonably good
	The parents can be relied upon to bring their child back for review

**Management in the eye department**

In high-income settings, babies diagnosed with dense bilateral cataract shortly after birth are not operated on until they are 6 weeks old. Surgery is somewhat easier at this age, and there are fewer short- and longer-term complications of surgery, particularly glaucoma.

Surgery is only the start of the care these children need; regular, long-term follow-up is essential to detect and manage complications and to ensure that children have the best optical correction. Frequent counselling of parents is required so that they understand their children’s need for life-long care.

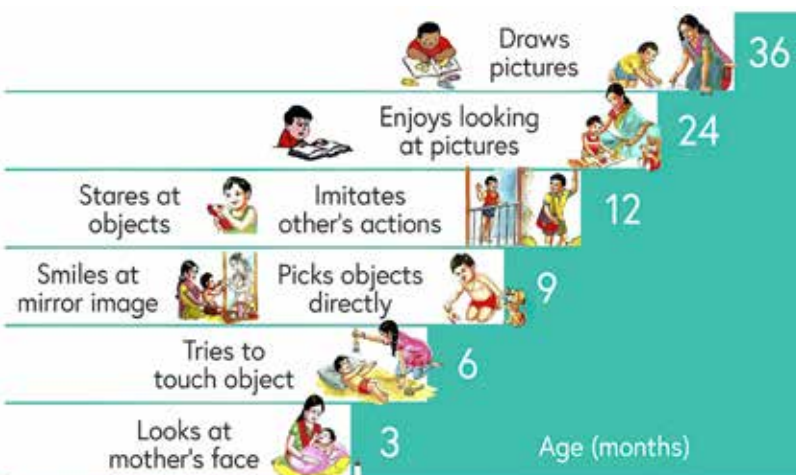
**Non-surgical management**

Conservative management is generally indicated only for small, partial cataracts that do not affect vision. Conservative management includes spectacle correction, patching, and dilation therapy to manage amblyopia. Follow-up is required to detect worsening of the signs and symptoms.

**Surgical management**

Surgery is the only treatment for significant bilateral cataracts. Lens wash-out, combined with posterior capsulotomy and anterior vitrectomy, is the preferred

**Figure 2** Visual milestones for children aged 3–36 months



procedure. The posterior capsule and anterior vitreous face should only be left intact in children aged over the age of five if good follow-up can be guaranteed and a YAG laser is available. Capsulotomy with anterior vitrectomy can be done from an anterior approach prior to intraocular lenses implantation or a posterior pars plana approach after IOL implantation into an intact capsular bag. Intracameral antibiotics may protect against postoperative endophthalmitis. Wilson et al have published a freely available and useful review on surgical techniques and which power intraocular lens to use.<sup>3</sup>

Children may not return promptly for surgery on their second eye, which can then become densely amblyopic. For this reason, surgery on both eyes during the same admission (note: not at the same time) is recommended. This also reduces costs and inconvenience for parents.

### Options for immediate correction of aphakia in children

- Intraocular lenses can be inserted during surgery in children if the corneal diameter is greater than 9 mm. The target refraction is hypermetropic, based on age, to take account of changes in refractive error as the eyes grow.<sup>3</sup> Biometry in children has to be done at the time of surgery. In high-income countries where contact lenses and glasses are readily accessible and replaceable, most surgeons do not insert an IOL below the age of 18 months, but in some low-income settings where follow up is poor, IOLs may be the best option for younger children.
- Contact lenses can be used, if available, for infants under the age of one and in microphthalmic eyes. Use may be limited by cost, as the lenses need to be changed frequently as the eyes grow. Parents need to accept them, and be able to insert, remove, and clean the lenses.
- Aphakic glasses are a safe and cost-effective method, but they require paediatric frames and careful dispensing. They are unsightly and heavy, and keeping them in position can be difficult. Loss and breakage are also big problems in settings where access to eye care and resources are limited.

If a child has been left aphakic, secondary intraocular lens implantation at any age over one year is possible if there are problems with contact lenses or glasses.

### Postoperative complications

Short-term postoperative complications include uveitis, corneal haze, dislocation of the intraocular lens, and wound leakage with or without iris prolapse. Removal of non-absorbable corneal sutures is important to prevent corneal suture abscesses.

Longer term complications include opacification of

the visual axis, which can be treated using YAG laser or surgically. Chronic glaucoma occurs in 10–25% of children following cataract surgery; the younger the age at surgery, the greater the risk. Glaucoma can be managed with topical medication, cyclo diode treatment, or angle surgery.

### Amblyopia

Amblyopia is the most common cause of low vision in young children after cataract surgery. This can be minimised by the following:

- **Early surgery**, particularly for congenital cataract
- **Accurate refractive correction** after surgery. Even in children with an intraocular lens, their refractive error will change with eye growth and spectacle correction will be required at times. Regular postoperative follow-up, with refraction and new spectacles when necessary, are essential. For children under 5 years of age, single vision spectacles corrected for near vision (a +3.00 add on top of cycloplegic refraction) are needed because they tend to interact with objects and people close to them. Bifocals are needed for children aged 5 years and above.
- **Intensive occlusion therapy** is essential after unilateral cataract surgery; it may be useful in children with bilateral cataracts if one eye is more amblyopic than the other.
- **Ensuring the visual axis stays clear.** Even if primary capsulotomy and anterior vitrectomy have been performed, secondary opacification is common, particularly in children with congenital cataract.

**“Amblyopia is the most common cause of low vision in young children after cataract surgery.”**

Spectacle correction and occlusion therapy, combined with frequent re-examination and acuity testing, are important. Amblyopia is challenging to manage in children who present late.

### Prevention

Rubella immunisation is now included in many national immunisation programmes, which should reduce congenital rubella syndrome. Treatment of eye or general conditions with topical or systemic steroids should be kept to a minimum, both in terms of the dose and the duration of treatment. Early detection, combined with high quality eye care and follow-up, maximise the chance of a good visual outcome.

The World Health Organization recommends that there is one tertiary level child eye care centre with a well trained and equipped team for every 10 million population. Counsellors and experienced optometrists are very important members of the team.



**Child wearing executive bifocal spectacles after cataract surgery.**

**BANGLADESH**

### Useful videos

CyberSight Webinar: Surgical management of congenital cataracts  
[www.youtube.com/watch?v=0ECya5f8ssA](http://www.youtube.com/watch?v=0ECya5f8ssA)

Paediatric surgery in Lahan, Nepal  
[www.youtube.com/watch?v=Qz1Vy8bcnag](http://www.youtube.com/watch?v=Qz1Vy8bcnag)

### References

- 1 Solebo AL, Cumberland P, Rahi JS; British Isles Congenital Cataract Interest Group. 5-year outcomes after primary intraocular lens implantation in children aged 2 years or younger with congenital or infantile cataract: findings from the IoLunder2 prospective inception cohort study. *Lancet Child Adolesc Health.* 2018;2(12):863-871.
- 2 Musleh M, Ashworth J, Black G, Hall G. Improving diagnosis for congenital cataract by introducing NGS genetic testing. *BMJ Open Quality.* 2016;5:u211094.w4602.
- 3 Wilson ME, Pandey SK, Thakur J. Paediatric cataract blindness in the developing world: surgical techniques and intraocular lenses in the new millennium. *Br J Ophthalmol.* 2003;87(1):14-19.





**Clare Gilbert**

Professor of International Eye Health: International Centre for Eye Health, London School of Hygiene & Tropical Medicine, London, UK.

# Corneal ulcers in children

It is vital to recognise and urgently treat corneal ulcers in children, as they can lead to permanent vision impairment. Children with corneal ulcers due to vitamin A deficiency also have an extremely high risk of mortality.

Although corneal ulcers can affect people of all ages, it is particularly important to recognise and treat them urgently in children, as ulcers can lead to scarring and complications that may impair a child's vision permanently. Children with corneal ulcers due to severe vitamin A deficiency are not only at risk of impaired vision, but also have an extremely high mortality rate: 60% are likely to die within 3 months, unless they are treated.

Other causes of corneal ulcers include injury/trauma, use of harmful remedies, autoimmune conditions, and infections due to viruses, bacteria, fungi, and protozoa. In this article, we focus on causes that are specific to children. For more information on managing corneal ulcers that affect people at any age, including those caused by bacteria and fungi, visit the *Community Eye Health Journal* online ([www.cehjournal.org](http://www.cehjournal.org)) and use the search function.

## What to look for and do at community/primary level

### Red eye and suspected corneal ulcer

Red eyes are common in children, and most resolve with appropriate care. However, the presence of one or more of these signs suggest that a child has developed a corneal ulcer and needs urgent treatment:

- The eye is watering excessively
- The child shows signs of being in pain
- The child shows signs of being sensitive to light
- The child can see less well (measurable as a decrease in visual acuity).

**What to do:** Immediately refer these children to an eye department where there is an ophthalmologist. If the child is up to 1 month of age, and has swelling of the eyelids as well as profuse, purulent discharge, this could be conjunctivitis of the newborn due to gonococcal infection (see page 4). Administer intramuscular antibiotics, if available (ceftriaxone 25–50 mg/kg, up to a maximum of 125 mg), and refer the child urgently.

### Vitamin A deficiency

Corneal ulcers due to vitamin A deficiency do not always cause a red eye, and are not painful (they may cause discomfort, however, and the child may keep their eyes closed). Suspect corneal ulcers due to vitamin A deficiency if:

- There is a recent or current history of fever, measles, or diarrhoea
- Both eyes are affected.

**What to do:** Immediately administer high-dose vitamin A (retinyl palmitate) and refer the child to a hospital. Follow up in 24 hours to ensure they are getting the help they need.

The recommended dose for each age group is:

- < 6 months of age: 50,000 international units (IU)
- 6–12 months: 100,000 IU
- > 1 year: 150,000 IU

Children must receive three doses of vitamin A: on day 1, day 2, and day 14.

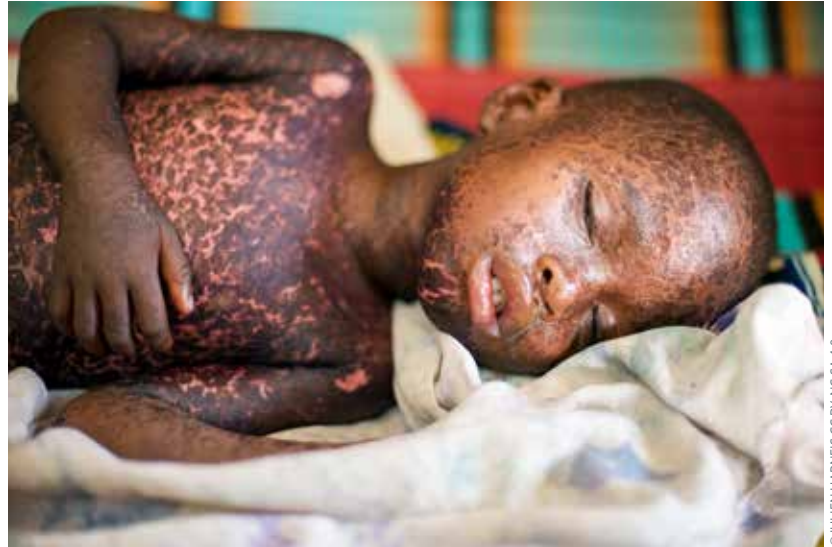## Diagnosis and management in the eye department

The table below lists the most common causes of corneal ulcers in children, alongside the age typically affected, the organism responsible (if any), and the history, diagnosis, and management of each condition.

## Prevention of corneal ulcers in children

Many of the causes of corneal ulcers in children can be prevented as follows:

- 1 Ocular prophylaxis of the newborn (cleaning the eyelids immediately after birth and instilling a topical antibiotic or antiseptic)
- 2 Measles immunisation and vitamin A supplementation.
- 3 Good hand hygiene and avoiding getting water in the eyes of contact lens wearers.
- 4 Preventing the use of harmful eye remedies, which requires measures such as health education and improved access to eye care services.





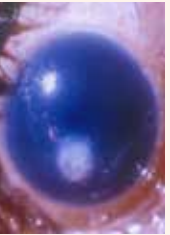



Measles infection is associated with corneal ulcers due to vitamin A deficiency, herpes simplex virus, and the use of traditional remedies. It is becoming more common due to declining immunisation coverage worldwide. GUINEA

© JULIEN HARNIS CC BY-NC-SA 4.0

## References

- 1 Jagadesh C. Reddy, Sayan Basu, Ujwala S. Saboo, Somasheila I. Murthy, Pravin K. Vaddavalli, Virender S. Sangwan, Management, Clinical Outcomes, and Complications of Shield Ulcers in Vernal Keratoconjunctivitis. *Am J Ophthalmol* 2013 155: 550-559.
- 2 Giuseppe Varacalli, Antonio Di Zazzo, Tommaso Mori, Thomas H. Dohlman, Sara Spelta, Marco Coassin et al. Challenges in Acanthamoeba Keratitis: A Review. *J Clin Med* 2021 10(5): 942.

# Common causes of corneal ulcers in children: history, diagnosis and management

Cause of the ulcer	Age of child	Infection?	History	Diagnosis	Management
<b>Conjunctivitis of the newborn (ophthalmia neonatorum)</b>  Corneal ulcer and abscess in gonococcal ophthalmia neonatorum. <b>TANZANIA</b>	< 1 month	Ophthalmia neonatorum can be due to a range of organisms, but only gonococcal infection causes corneal ulcers and corneal abscesses.	Lid swelling and profuse, purulent discharge	Conjunctival swab with microscopy (Gram stain)	If gonococcal infection is confirmed, give ceftriaxone as a single dose of 25–50 mg/kg intramuscular or intravenous, up to a maximum of 125 mg. The mother and her sexual partner also need to be treated.
<b>Corneal infection (microbial keratitis)</b>  Often associated with trauma to the eye and usually caused by fungi or bacteria, with <i>Acanthamoeba</i> sp. a less common cause.	Any age	Yes – bacteria, fungi and/or protozoa ( <i>Acanthamoeba</i> sp.)	Trauma to the eye, e.g. with plant matter, dust, use of topical traditional medicines or poor contact lens hygiene.	Corneal scrape with microscopy (Gram stain) and culture. Suspect <i>Acanthamoeba</i> sp. if culture is negative for bacteria and fungi and there is a history and clinical signs suggestive of this type of infection; positive diagnosis is challenging, requiring PCR or confocal microscopy.	Intensive topical treatment, guided by laboratory results Read more here: Clinical diagnosis and management <a href="http://tinyurl.com/mkman">http://tinyurl.com/mkman</a> Taking a corneal scrape <a href="http://tinyurl.com/mksrape">http://tinyurl.com/mksrape</a>
<b>Vitamin A deficiency/measles</b>  Corneal ulcer due to acute vitamin A deficiency. Note that the cornea is dry and slightly hazy, and the eye is not very inflamed. <b>TANZANIA</b>	< 5 years	No. There may be corneal melting (keratomalacia)	Fever, measles, diarrhoea, inadequate nutrition, (often associated with poverty)	Clinical suspicion/medical history	High-dose vitamin A Topical antibiotics if there is secondary infection
<b>Harmful eye remedies</b>  Atypical corneal ulcer in a girl treated using her uncle's urine, which was infected with <i>Neisseria gonorrhoeae</i> . <b>SIERRA LEONE</b>	Any age	Depends on what was put in the eye(s)	Measles infection or conjunctivitis. Note: carers may not give a history of use	Corneal scrape with microscopy (Gram stain) and culture	Intensive topical treatment, guided by laboratory results
<b>Herpes simplex</b>  Dendritic ulcer due to Herpes simplex stained with fluorescein. <b>TANZANIA</b>	Any age	Yes, viral infection	Recent measles infection. May be recurrent.	Clinical diagnosis	Treat using topical antiviral agents, such as acyclovir and ganciclovir. Close follow-up is needed.
<b>Severe vernal keratoconjunctivitis</b>  Shield ulcer complicating severe vernal keratoconjunctivitis. <b>INDIA</b>	Older children/ adolescents	No	Chronic irritation, watering with stringy discharge May have other allergies such as eczema or asthma	Clinical examination for typical signs of vernal keratoconjunctivitis: <ul style="list-style-type: none"> <li>• Limbal papillae</li> <li>• Cobblestone or giant papillae respectively</li> <li>• Scarring of the upper tarsal plate.</li> </ul> See previous CEHJ article about vernal keratoconjunctivitis: <a href="http://tinyurl.com/y6wv8p9x">http://tinyurl.com/y6wv8p9x</a>	Shield ulcers can be graded depending on their severity: <sup>1</sup> <b>Grade 1</b> An ulcer with a clear/transparent base. Usually responds to medical treatment alone (to control inflammation and allow the cornea to heal). Topical anti-inflammatory eye drops including sodium chromoglycate and topical cyclosporin can be used. Topical steroids are not advised due to the risk of secondary cataract and glaucoma; however, sub tarsal injection of long-acting, depot steroids can be used. <b>Grade 2</b> An ulcer with a translucent base (i.e., it lets some light through), with or without opaque white or yellow deposits (inflammatory debris). The deposits filling the ulcer need to be gently removed and the eye padded. <b>Grade 3</b> An ulcer which has elevated plaque formation. These ulcers may need an amniotic membrane graft to promote healing.



**Richard Bowman**  
 Honorary Clinical Consultant:  
 International Centre for Eye Health,  
 London School of Hygiene & Tropical  
 Medicine, London, UK.



**P Vijayalakshmi**  
 Senior Paediatric Ophthalmologist  
 and Chief of Vision Rehabilitation  
 Centre: Aravind Eye Care System,  
 Madurai, India.

# Cerebral visual impairment

Children with cerebral visual impairment can be helped to make the most of their vision, but early intervention is vital.

Cerebral vision impairment (previously called cortical vision impairment) includes all visual problems caused by brain damage.<sup>1</sup> Children with cerebral palsy, due to damage to the parts of the brain which control movement, can also have cerebral vision impairment.

In cerebral vision impairment, the eyes can be completely healthy, but children struggle with one or more of the following:

- Seeing clearly (due to poor visual acuity)
- Recognising people and things which are familiar
- Difficulty going down steps or stairs due to lower visual field defects
- Functioning in a cluttered or visually 'busy' environment (e.g., struggling to find objects)
- Coordinating movements that depend on vision (e.g., picking up a small object).

If parents and teachers do not recognise that the child's challenges are due to a problem with their brain, they may think that the child is being uncooperative, disobedient, or clumsy.

Cerebral vision impairment is increasing in importance in low- and middle-income countries. This is because prematurity is an important cause of cerebral vision impairment, and – as a result of improvements in neonatal care in many low- and middle-income countries – premature babies are now surviving in greater numbers.

Brain damage associated with cerebral vision impairment cannot usually be treated. However, families can be supported to make changes in their home or how they interact with their child, based on their child's unique combination of difficulties, and this can improve the quality of their child's life.

Early intervention is vital – the younger a child is, the more their brain will be able to adapt and make good use of the support they receive.

## How does cerebral visual impairment affect children?

Cerebral visual impairment can cause any combination of the following, to a greater or lesser degree:

- Loss of visual acuity



Children with cerebral visual impairment should have their refractive errors corrected. They can be taught 'active looking' by increasing their awareness of their hands and feet and encouraging them to reach out and touch the objects they are trying to look at. **BANGLADESH**

- Falling over objects or difficulty going downstairs due to lower visual field defects
- Visual perception problems, such as difficulties moving around in cluttered or changing environments or not being able to find their way alone along a familiar route.

It is important to understand the wide variety of difficulties children with cerebral vision impairment can have, as coping strategies need to be tailored to the unique combination of difficulties experienced by each child.

## What causes cerebral vision impairment?

Children are either born with cerebral vision impairment, or it occurs during the first few years of life, following brain injury from a range of causes (Table 1).<sup>2</sup> Cerebral vision impairment is common amongst children with cerebral palsy and special educational needs, such as cognitive/intellectual disabilities and/or autism.<sup>3</sup>

**Table 1** Causes of cerebral vision impairment in high- and low-income settings

Cause	Low income**	High income
Prematurity	+++++	+++++++
Neonatal sepsis	++++	+++
Birth asphyxia	++++	++
Meningitis	++	+
Neonatal jaundice	++++	+ / -
Cerebral malaria	++	-
Genetic conditions	-	+

\*\*Limited data are available.



## What to look for at the local/primary level and when to refer

The following children must be *referred to the nearest eye centre where there is a paediatric ophthalmologist*, particularly if they have never been examined by one before:

- 1 All children with **cerebral palsy**. Some of the difficulties children with cerebral palsy have with everyday tasks or movement can be due to problems with their vision, not the cerebral palsy. Parents may not realise this, as their child's eyes appear normal.
- 2 Children with special educational needs, such as **cognitive/intellectual disabilities and/or autism**. Cerebral visual impairment can exacerbate these children's difficulties, as good vision is needed for normal intellectual and social development. Parents and health care personnel may attribute signs of cognitive visual impairment to the child's other condition.
- 3 All children who were **born very prematurely or who have had difficult births**, particularly if they were deprived of oxygen during delivery (birth asphyxia); these children are at high risk of cerebral palsy and cerebral visual impairment.
- 4 Children with a history of **neonatal sepsis, neonatal jaundice, and/or cerebral malaria** (see Table 1).
- 5 Otherwise healthy children, **if their parents or carers say that they have noticed the problems outlined on page 20 once their child is old enough to walk around**. The child may fall over things on the floor, struggle to see things that are moving quickly (like birds or animals), struggle to recognise people they know, or struggle to find their way to school on their own – even though they have travelled there several times before.

## What care do these children need?

Children who may have cerebral vision impairment must undergo an assessment of their **visual functioning** (visual acuity and visual fields), and an assessment to determine whether they have any problems with processing vision (visual perception).

Specialists can then explain to parents how they can support their child to make the best use of the vision they have, which will help their development.

## Diagnosis at the tertiary level

Cerebral vision impairment is initially diagnosed clinically, after ruling out eye conditions that could be responsible for poor vision. The diagnosis can sometimes be supported by a computed tomography (CT) or magnetic resonance imaging (MRI) scan, where available.

All children with developmental delays and/or cerebral palsy should be assessed.

- 1 Start by asking whether there is a history of any of the conditions which can cause brain damage in children (Table 1).
- 2 Ask whether the parents/carers have noticed any problems which they think might be due to their child not seeing normally.
- 3 Ask about visual milestones and test whether the child has reached the milestone appropriate for their age. For example, for a 9-month-old, put a small, bright object in front of them to see if they look at it and/or try to reach for it.

- 4 Measure visual acuity using age- and ability-specific tests, if possible.
- 5 Carry out refraction; cycloplegia may be needed.
- 6 Assess other visual functions, i.e., visual field, contrast sensitivity, colour vision, and depth perception.
- 7 Assess eye movements.
- 8 Check pupil reactions, the clarity of the ocular media, and the optic discs.

For children who are old enough to walk, ask the parents/carers a series of questions to assess the child's higher visual processing:

- 1 Does your child have difficulty going down steps or stairs?
- 2 Does your child have difficulty seeing things which are moving quickly, such as a bird or small animal, or a ball that is thrown?
- 3 Does your child have difficulty seeing something which is pointed out to them in the distance?
- 4 Does your child have difficulty locating an item of clothing in a pile of clothes?
- 5 Does your child find drawing or copying letters or words difficult and time-consuming?

If the parent/carer says yes to more than three of these questions, it is likely that the child has visual perception problems.

More specialised tests of visual function, which need to take into account the child's age, ability and level of cooperation, include testing their ability to:

- Detect small objects
- Discriminate two spatially separated targets (such as Lea paddles)
- Fixate on and follow a moving target
- Discriminate shape, size, and colour.

## Management at the tertiary level

A key principle in managing visual and neurodevelopmental problems in children is the importance of **early intervention**. This is because the young brain can change more readily than an older brain (i.e., is has more 'plasticity').

As with any other child, significant refractive errors should be corrected. Children with cerebral palsy and other conditions of the brain often have poor accommodation. Spectacles with a near add can be very helpful even in young children, as good near vision is important for interacting and bonding with their mother.<sup>4</sup> Yoked prisms (base-down prisms in front of both eyes) are useful for managing lower visual field defects.

Children can also be helped to make the most of the vision they have, by providing 'active visual stimulation'.<sup>4</sup> The basis of this approach is that vision is the sense which coordinates other sensory input. Without vision, or with poor vision, it is harder for children to make sense of their environment and to learn. Children can be taught 'active looking' by increasing their awareness of their hands and feet and encouraging them to reach out and touch the objects they are trying to look at. Carers must provide verbal explanations of what the child is experiencing in terms of what they are touching, tasting, or hearing to enable them to gain a better understanding of the world around them.

**“A key principle in managing visual and neurodevelopmental problems in children is the importance of early intervention.”**



© UN WOMEN/SECOND CHANCE EDUCATION PROGRAMME CC-BY-NC 4.0

Another approach, which shows promise, is to tailor what can be done to address the specific problems of an individual child. For example, if a child cannot find something amongst a group of other items, make the visual environment simpler by removing any unnecessary items.

Difficulty going down steps may be due to a lower field defect and/or poor visual-motor coordination of the feet (in addition to any motor problems with the feet/legs). Strategies might include wearing brightly coloured shoes, feeling for the edge of the step with the feet, or using a stick to provide sensory contact with the ground. If a child cannot recognise a parent amongst a group of other people, the parent could wear an item of clothing of an agreed colour.<sup>5,6</sup> A list of possible interventions can be found at [tinyurl.com/cviguide](https://tinyurl.com/cviguide). The CVI Scotland website (<https://cviscotland.org/>) has a lot of helpful

information including videos and animations which help us to experience what it might be like to have some of the visual difficulties experienced by children with cerebral vision impairment.

### Counselling parents and carers

All parents/carers of children with cerebral visual impairment must be given a clear, understandable explanation of what is wrong and why this might have happened. Knowing that their child has a physical problem with seeing or understanding what they see can make parents realise that their child is not being naughty, difficult, or disobedient. This can change attitudes and relationships. Where possible, teach parents how to adapt to the needs of the child, as described in the previous section.


**Agreeing a colour to wear (red) will help a child with cerebral vision impairment to find their mother in a crowd of women. INDIA**

### References

- 1 Kozeis N. Brain visual impairment in childhood: mini review. *Hippokratia*. 2010 Oct;14(4):249-51.
- 2 Duke RE, Nwachukwu J, Totty C, Okorie U, Kim MJ, Burton K et al. Visual impairment and perceptual visual disorders in children with cerebral palsy in Nigeria. *Br J Ophthalmol*. 2022;106(3):427-434.
- 3 Chokron S, Kovarski K, Zalla T, et al. The inter-relationships between cerebral visual impairment, autism and intellectual disability. *Neurosci Biobehav Rev*. 2020;114:201-10.
- 4 Sonksen PM, Petrie A, Drew K. Promotion of visual development of severely visually impaired babies: evaluation of a developmentally based programme. *J Dev Med Child Neurol*. 199;33(4):320-35.
- 5 Tzirka A, Liasis A, Kuczynski A, et al. Clinical use of the Insight Inventory in cerebral visual impairment and the effectiveness of tailored habilitational strategies. *Dev Med Child Neurol*. 2020;62(11):1324-30.
- 6 Duke RE, Chimaeze T, Kim MJ, Ameh S, Burton K, Bowman R. The effect of insight questions inventory and visual support strategies on carer-reported quality of life for children with cerebral palsy and perceptual visual dysfunction in Nigeria: A randomized controlled trial. *Front Hum Neurosci*. 2021;15:706550.

# New World Health Organization guidelines

WHO has published two new documents relevant to child eye care.



The World Health Organization (WHO) standards for improving the quality of care for small and sick newborns in health facilities has been updated; it now recommends identifying, screening and treating infants at risk of retinopathy of prematurity (ROP) as an evidence-based practice to improve the quality of intensive neonatal care. You can use this recommendation to advocate with ministries of health for more services for ROP in your country.

Quality statement 1.33 (new) states: **Small and sick newborns at risk of retinopathy of prematurity are appropriately identified, screened and treated.**

Download the document from [tinyurl.com/WHOrop](https://tinyurl.com/WHOrop)

WHO recommends that all newborns have their eyes screened as part of the general newborn assessment, to detect abnormalities such as cataract and retinoblastoma. This recommendation can be used to advocate with ministries of health to ensure eye screening is included in their child health programmes.

Recommendation 26 states: **Universal newborn screening for abnormalities of the eye is recommended and should be accompanied by diagnostic and management services for children identified with an abnormality.**

Download the document from [tinyurl.com/WHOmat-care](https://tinyurl.com/WHOmat-care)

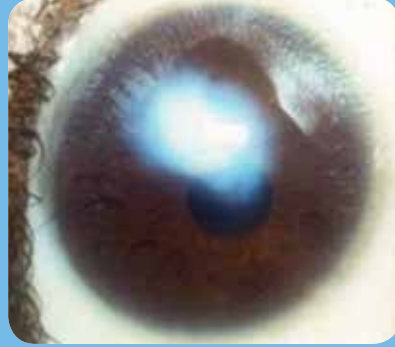
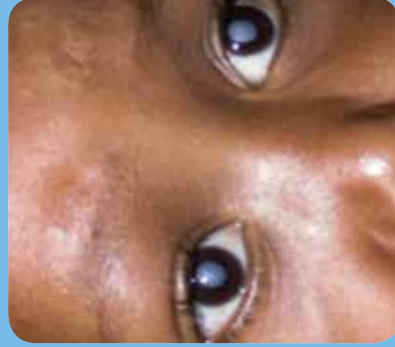
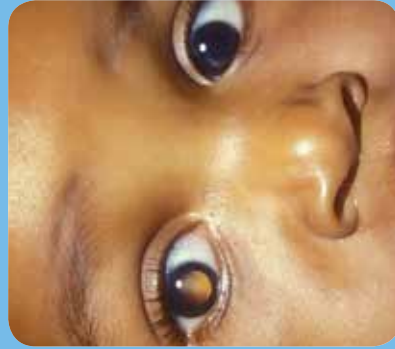# Important messages for eye health in babies and young children

Sharing the information in this poster with parents and carers can help to prevent life-long visual impairment and blindness in babies and young children. If you can, download the poster from our website ([www.cehjournal.org](http://www.cehjournal.org)), print it in colour, and display it at your local primary care facility.

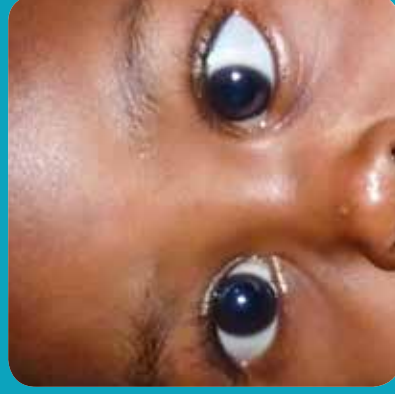## Have you noticed something white in the eye or eyes of your child?

If so, tell the staff in the clinic



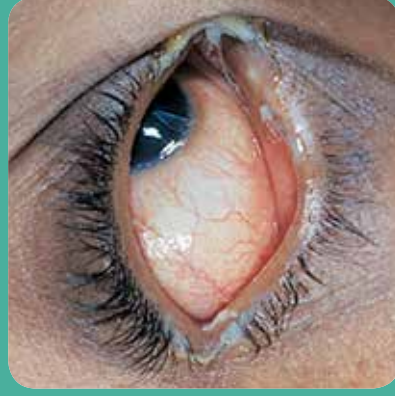## Does your child have a squint?

Tell the staff



## Does your child have red, sticky, or watering eyes?

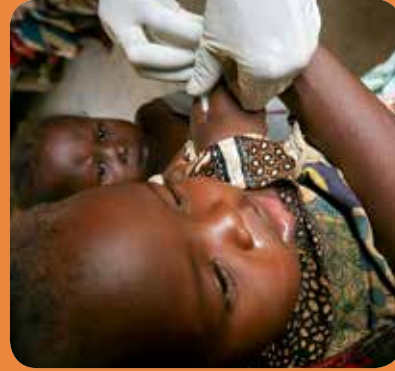Tell staff in the clinic



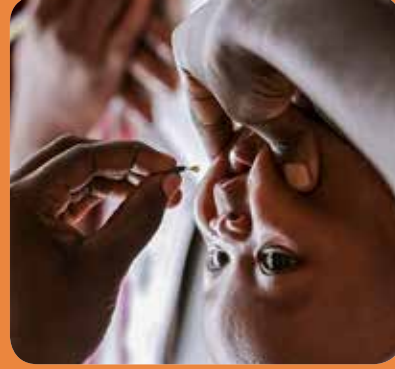## Is your child's eye painful, or you are worried they might not see normally?

If you have noticed anything wrong with your child's eye or eyes, tell the staff in the clinic

## How you can prevent eye disease and keep your child's eyes healthy



Measles immunisation at 9 months of age



Vitamin A every 6 months from 6 months of age



Give your child coloured fruits and vegetables at least once a day



Do not use traditional eye remedies if your child has an eye problem